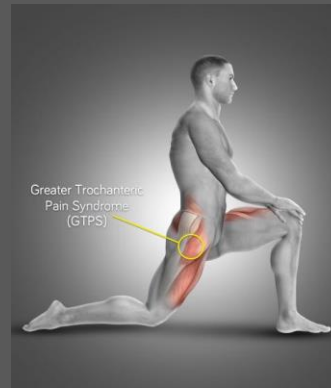
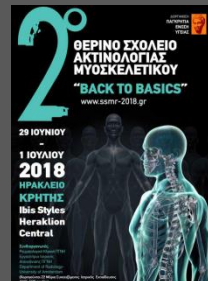
# ΣΥΝΔΡΟΜΟ ΕΠΩΔΥΝΟΥ ΜΕΙΖΟΝΟΣ ΤΡΟΧΑΝΤΗΡΑ

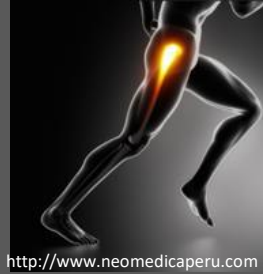

Γιώργος Μαντζικόπουλος  
ΓΝΑ ΚΑΤ



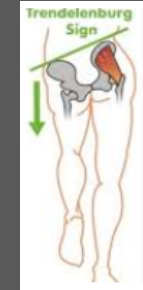♀ 40 – 60 χρ. (♀ : ♂ 4:1), αθλητές, ΤΗΑ

συχνότητα : 10-25%



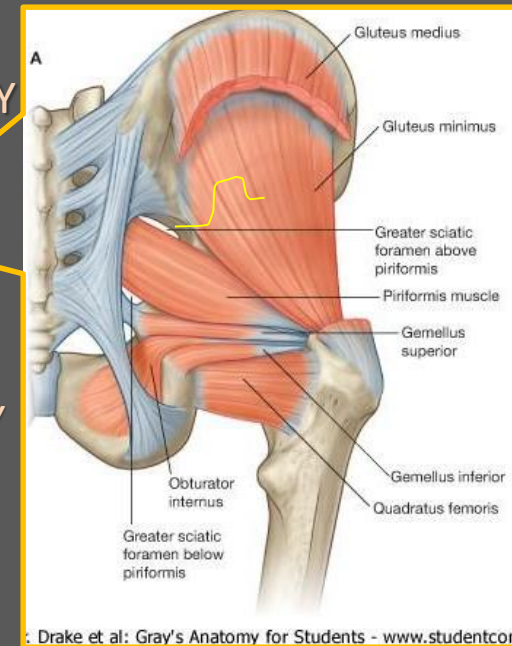
<http://www.neomedicaferu.com>

- ΑΛΓΟΣ ΣΤΗΝ ΠΕΡΙΟΧΗ ΤΟΥ Μ. ΤΡΟΧΑΝΤΗΡΑ, ΜΕ ΠΙΘΑΝΗ ΕΠΕΚΤΑΣΗ ΣΤΟ ΕΞΩ ΠΛΑΓΙΟ ΤΟΥ ΜΗΡΟΥ
- ΕΠΙΔΕΙΝΩΣΗ ΤΟΥ ΑΛΓΟΥΣ ΣΕ ΚΑΤΑΚΛΙΣΗ ΕΠΙ ΤΟΥ ΠΑΣΧΟΝΤΟΣ ΠΛΑΓΙΟΥ
- ΑΛΓΟΣ ΜΕΤΑ ΑΠΟ ΔΡΑΣΤΗΡΙΟΤΗΤΕΣ ΠΟΥ ΦΟΡΤΙΖΟΥΝ ΤΟ ΣΚΕΛΟΣ
- ΠΙΘΑΝΗ ΜΥΪΚΗ ΑΔΥΝΑΜΙΑ - Trendelenburg's sign
- ΤΡΑΥΜΑ, ΠΑΡΑΤΕΤΑΜΕΝΗ ΠΙΕΣΗ , ΕΠΙΠΟΝΗ ΑΣΚΗΣΗ, ΠΑΡΑΤΕΤΑΜΕΝΗ ΦΟΡΤΙΣΗ ΤΟΥ ΣΚΕΛΟΥΣ, ΑΣΤΑΘΕΙΑ ΤΟΥ ΙΣΧΙΟΥ.

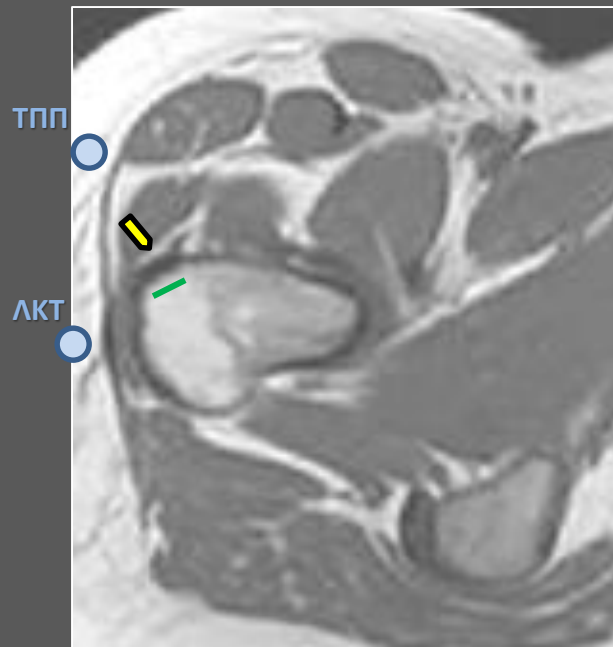
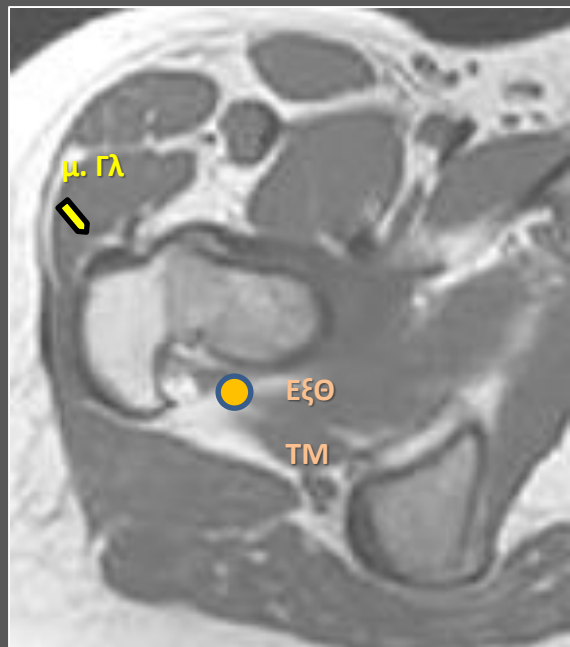
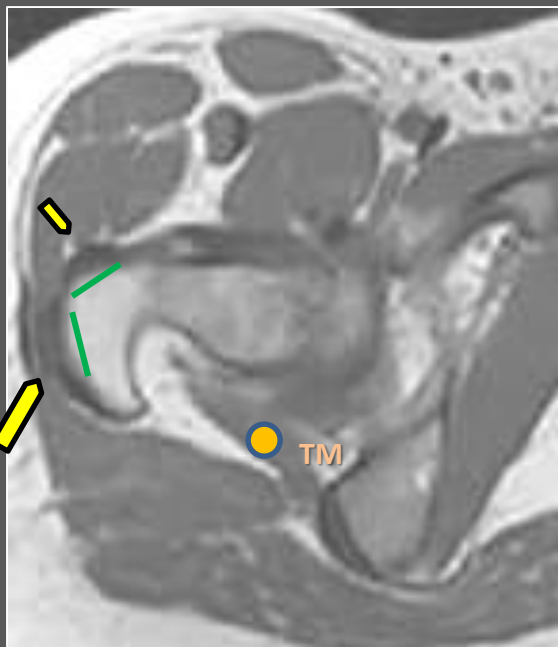
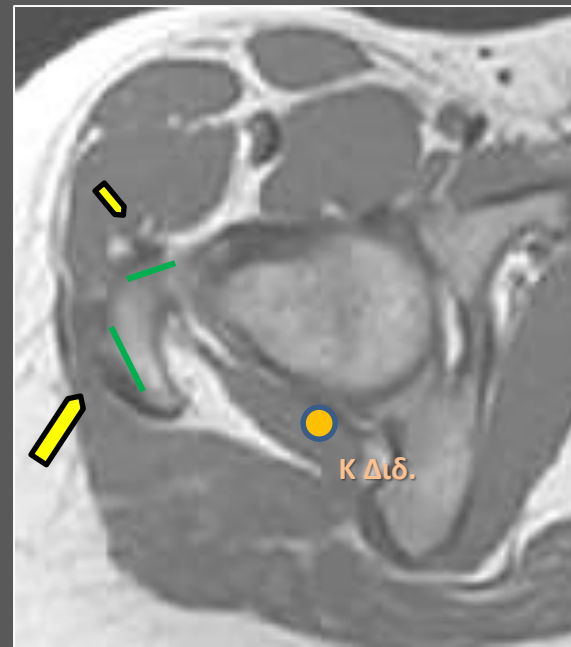
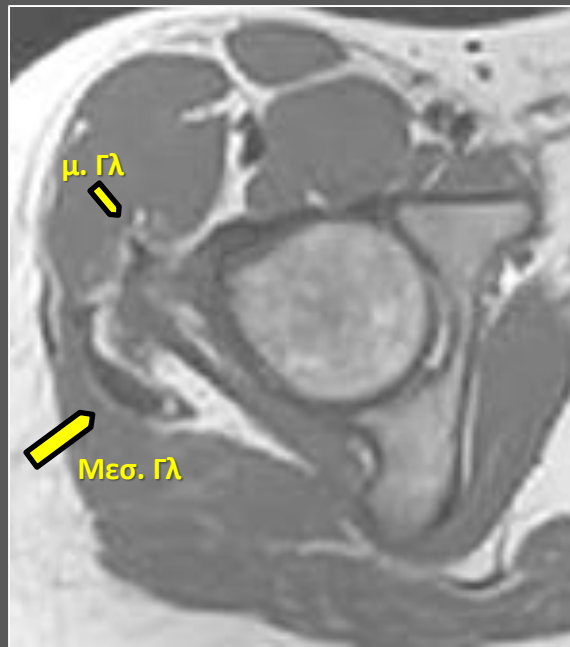
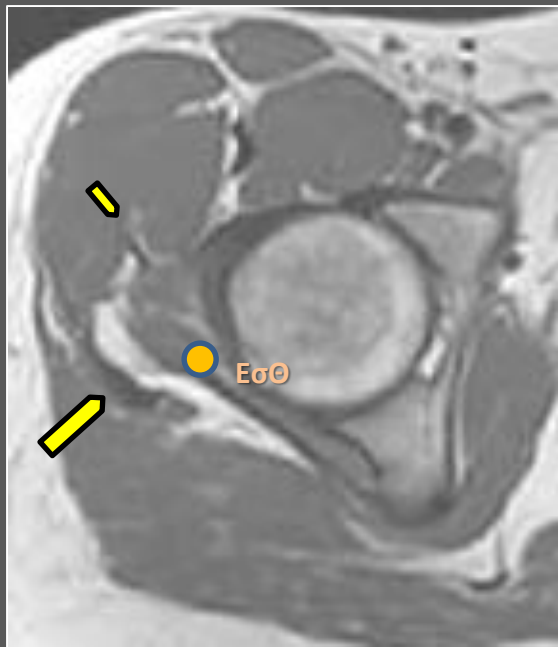


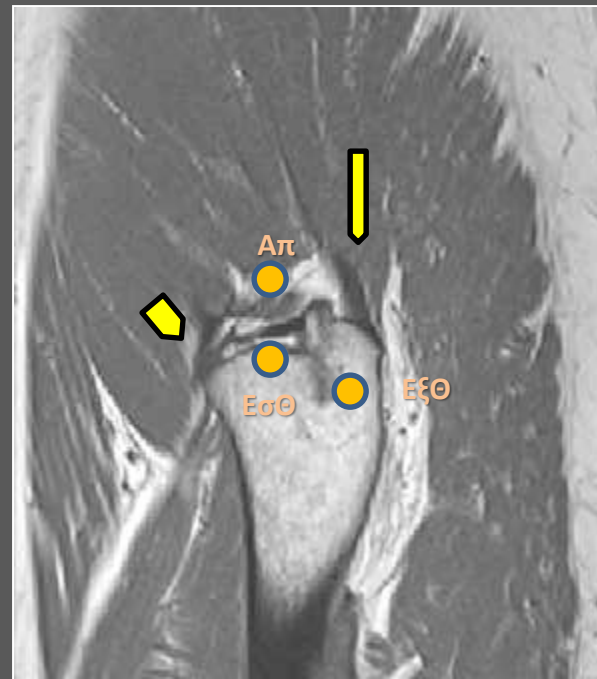
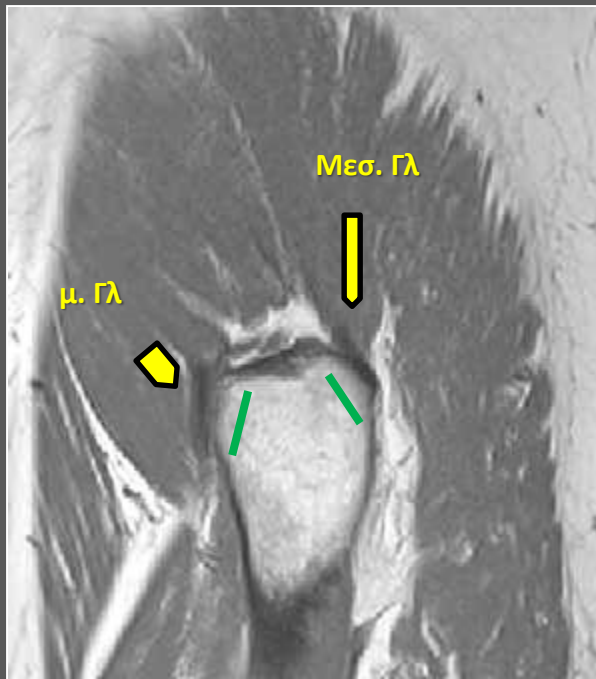
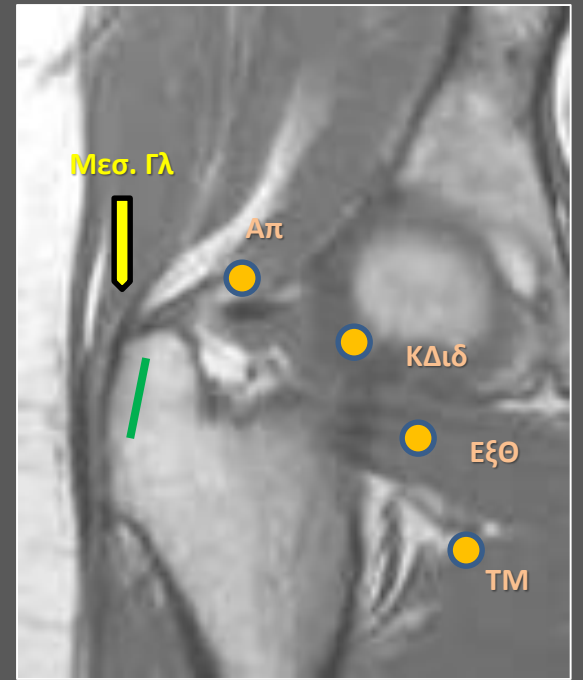
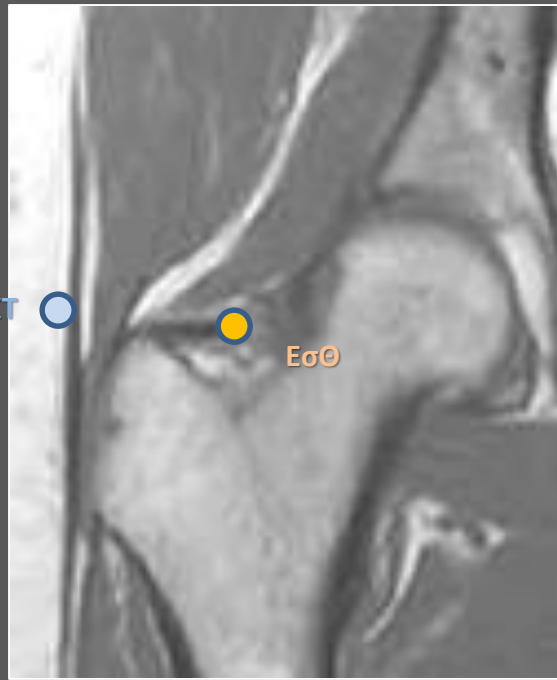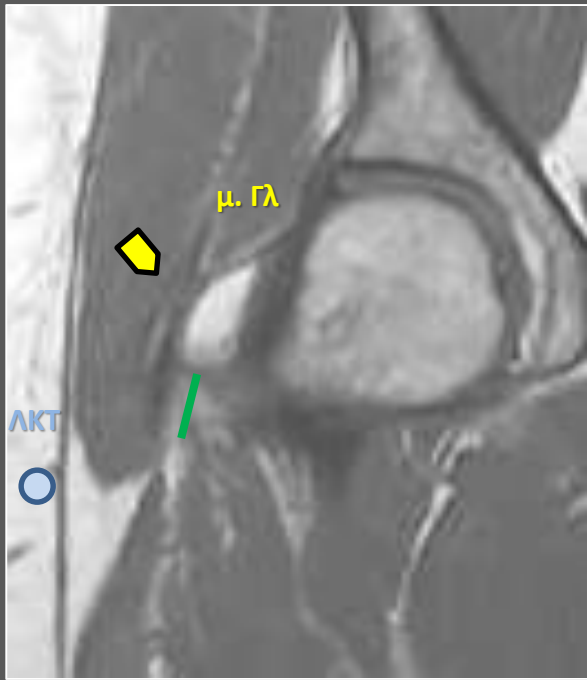
### ΘΥΛΑΚΙΤΙΣ ΤΟΥ Μ. ΤΡΟΧΑΝΤΗΡΑ

- ΤΕΝΟΝΤΟΠΑΘΕΙΑ ΤΟΥ μικρού ΓΛΟΥΤΙΑΙΟΥ & μέσου ΓΛΟΥΤΙΑΙΟΥ
- ΠΑΧΥΝΣΗ ΤΗΣ ΛΑΓΟΝΟΚΝΗΜΙΑΙΑΣ ΤΑΙΝΙΑΣ
- ΤΕΝΟΝΤΟΠΑΘΕΙΑ ΤΩΝ ΒΡΑΧΕΩΝ ΣΤΡΟΦΕΩΝ ΤΟΥ ΙΣΧΙΟΥ  
( τετράγωνος μηριαίος, απιοειδής,  
έσω κ. έξω θυροειδής, άνω κ. κάτω δίδυμος)
- ΡΗΞΕΙΣ ΤΩΝ ΤΕΝΟΝΤΩΝ ΤΟΥ μ. ΓΛΟΥΤΙΑΙΟΥ & μέσ. ΓΛΟΥΤΙΑΙΟΥ
- COXA SALTANS
- ΤΗΑ



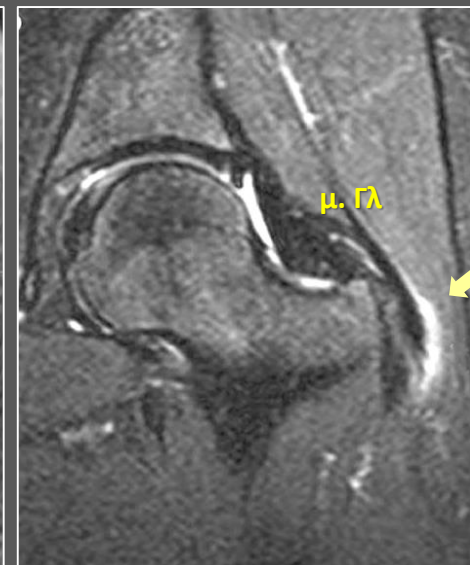
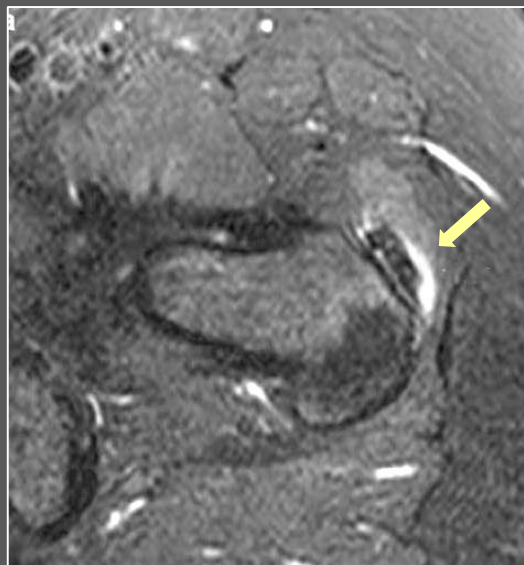Drake et al: Gray's Anatomy for Students - www.studentcon



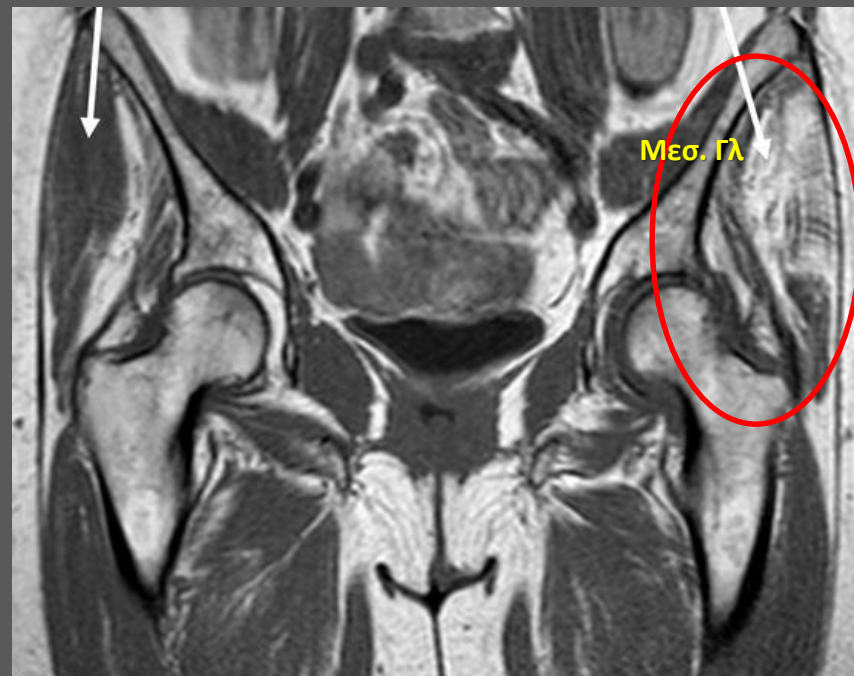
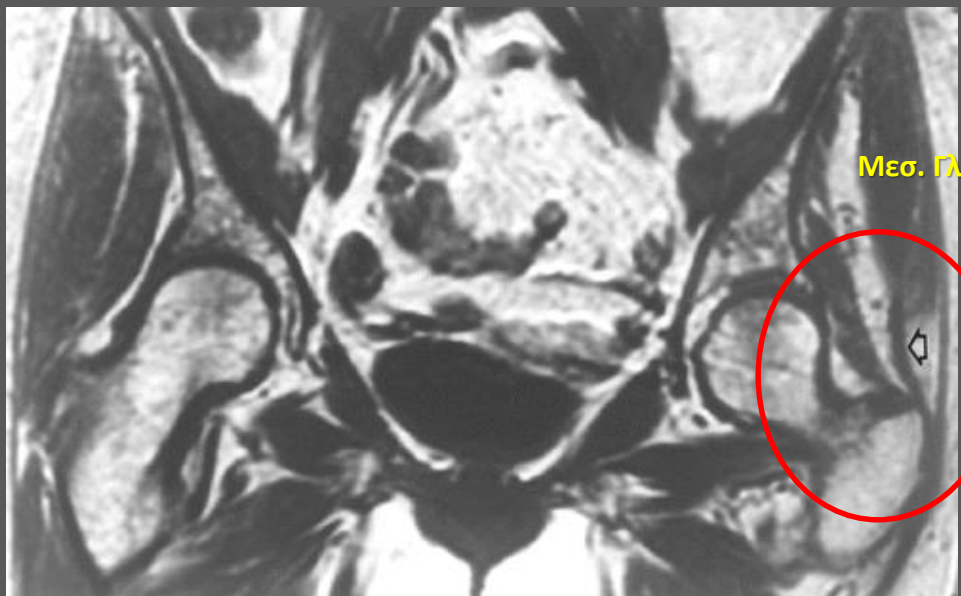


# Τενοντοπάθεια

- Τενοντοπάθεια των απαγωγών είναι το συχνότερο εύρημα ( πρόσθιες ίνες Μέσου γλουτιαίου )
- Ενθεσόφυτα > 2cm
- Λιπώδης μυϊκή ατροφία
- HADD
- Ανατομικές Ανωμαλίες της Κοτύλης (CEa , AA)
- ! Ρευματική πολυμυαλγία και Σπονδυλοαρθροπάθεια  
↓  
Ενθεσίτιδα, Θυλακίτιδα



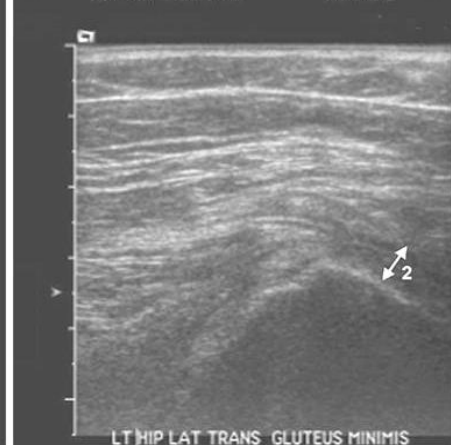
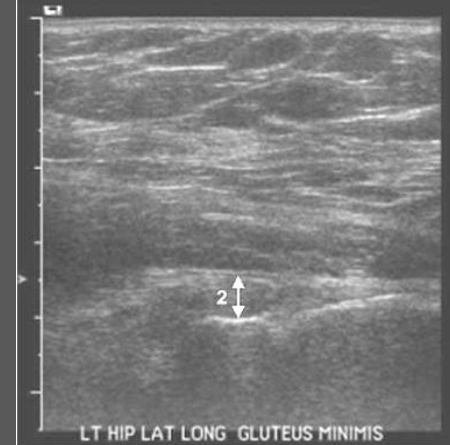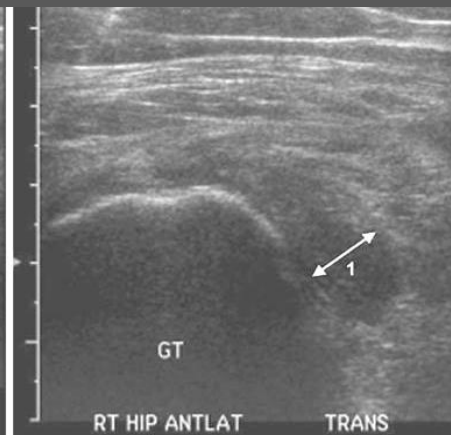
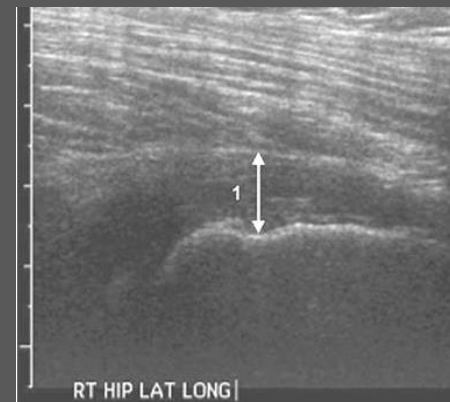
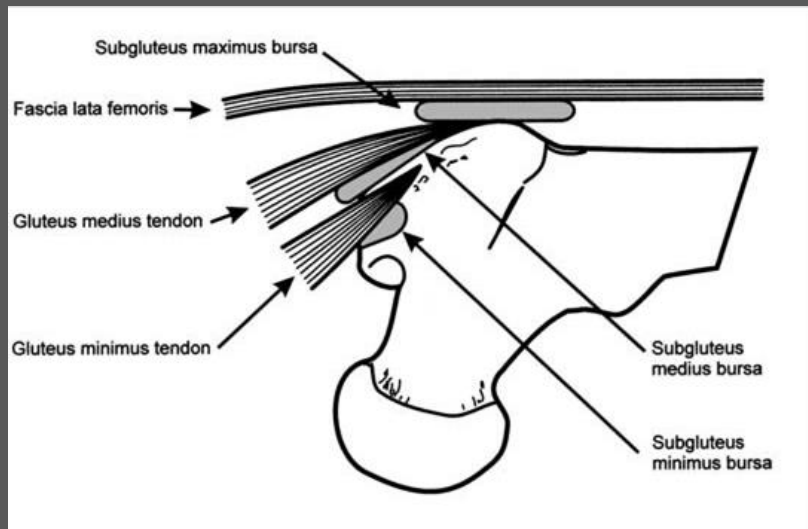
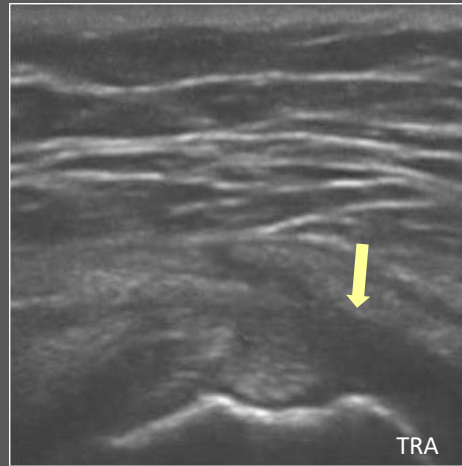
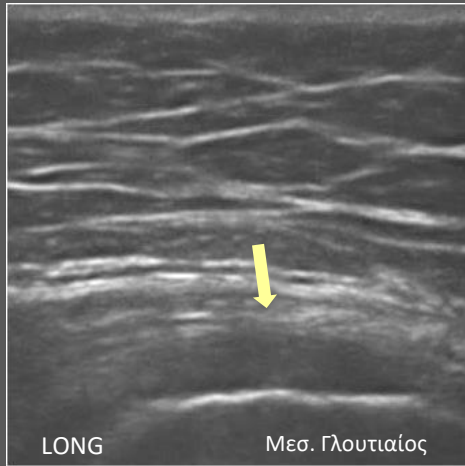
↓ κολλαγόνο 1 ↑ κολλαγόνο 2 = ↓ μηχανικής αντοχής



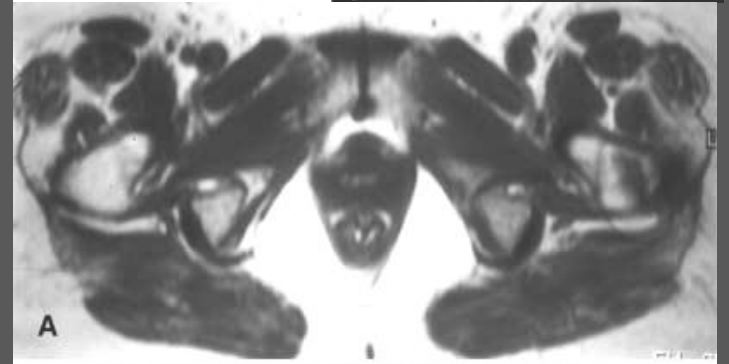
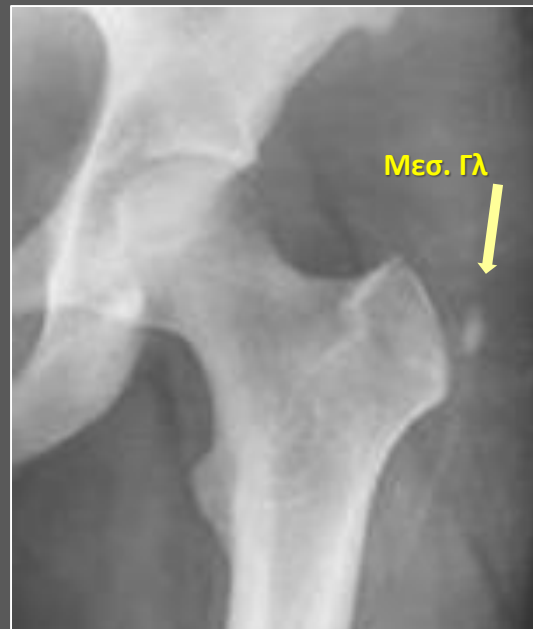
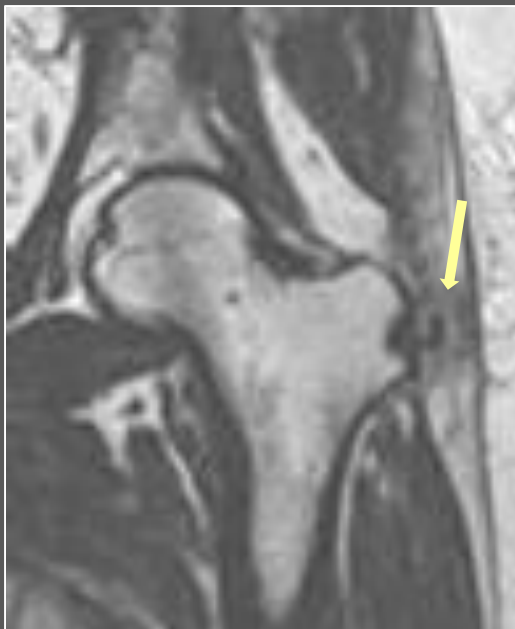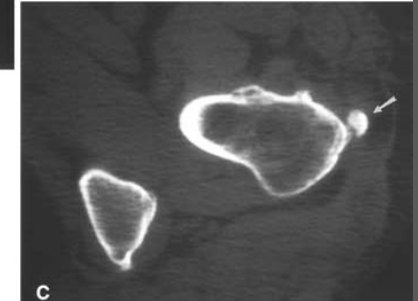
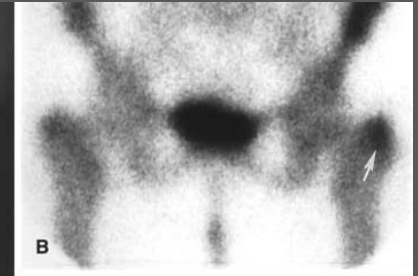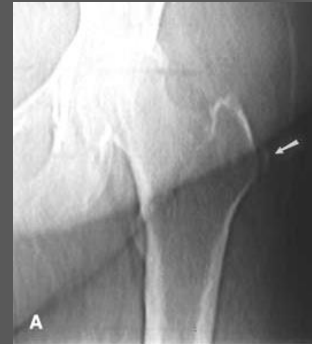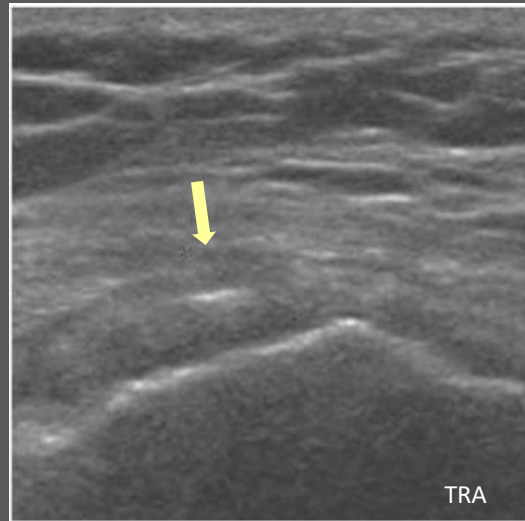
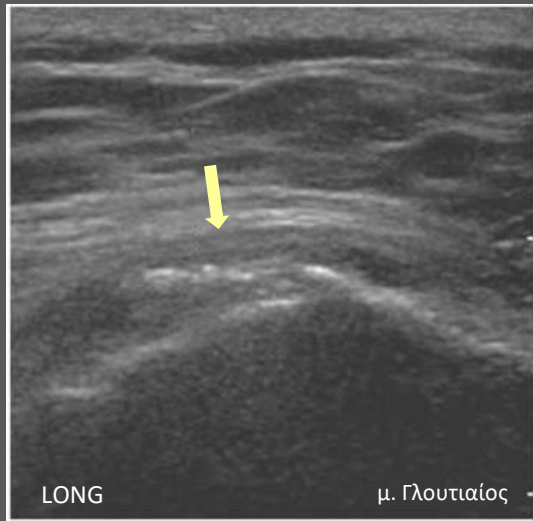
# Τενοντοπάθεια

Τενοντοπάθεια γλουτιαίων / θυλακίτιδα του Τροχαντήρα / λαγονοκνημιαία ταινία

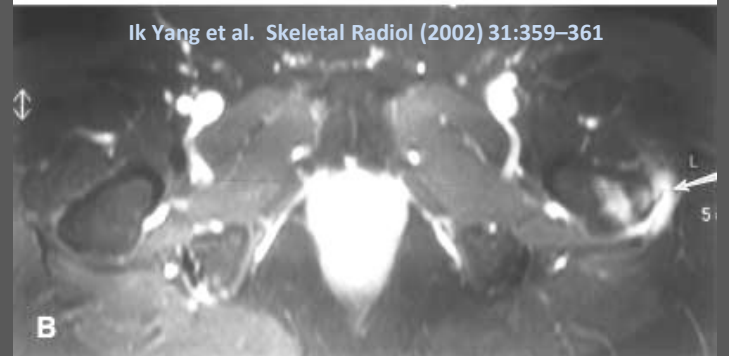- ↓ Ηχωγένειας ( οίδημα + βλεννομυξώδης εκφύλιση)
- ≈ Ηχωγένεια
- Πάχυνση



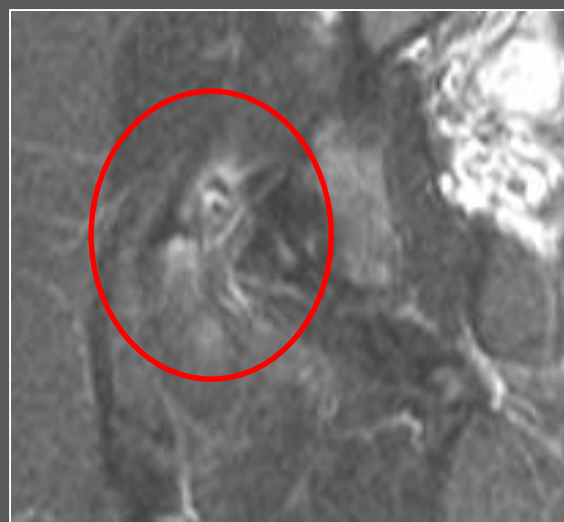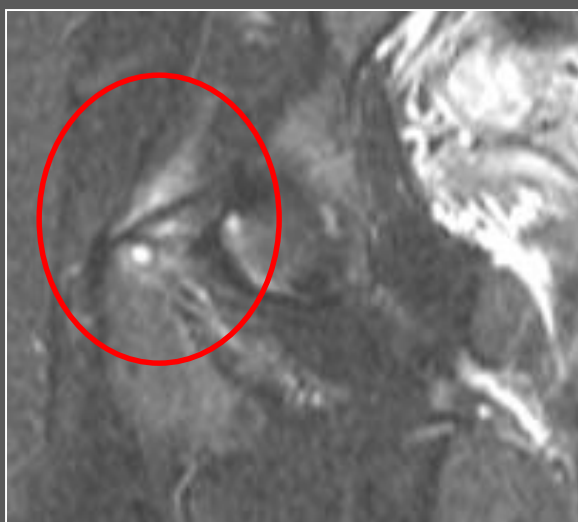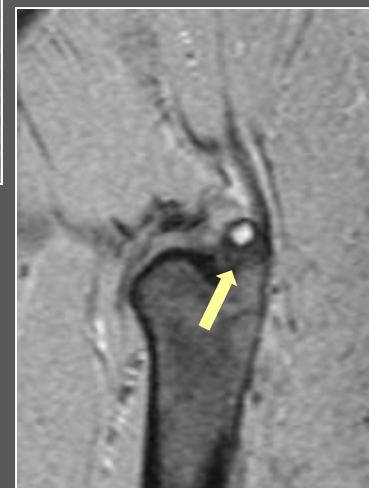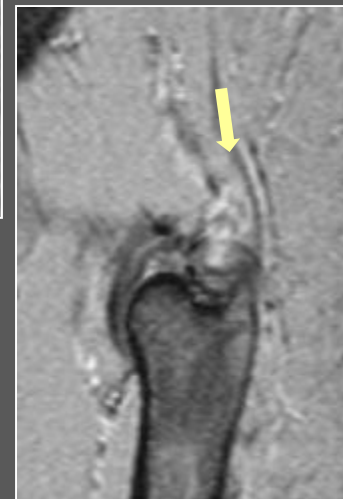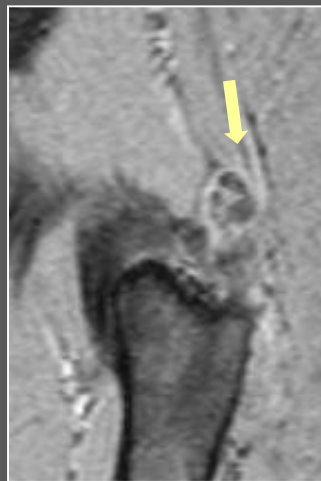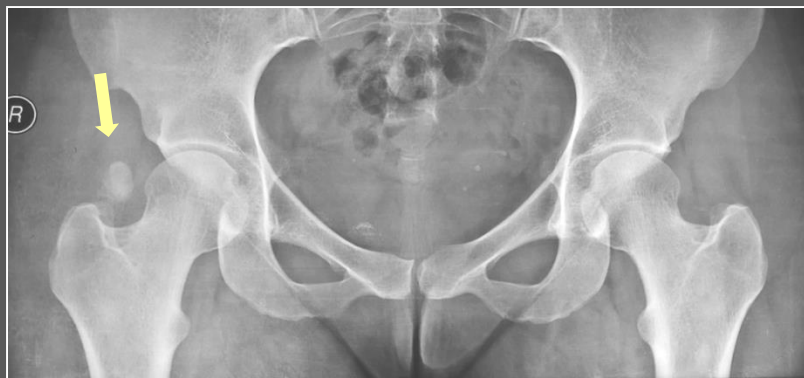# Τενοντοπάθεια και Ασβεστοποιός τενοντίτις



Ik Yang et al. Skeletal Radiol (2002) 31:359–361



♀ 27 χρ Άλγος Δεξιού Ισχίου

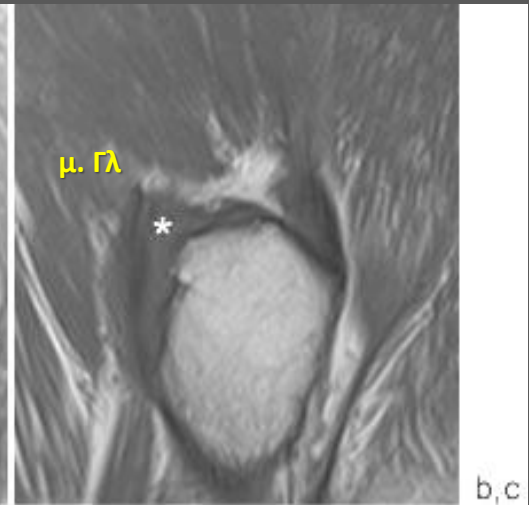
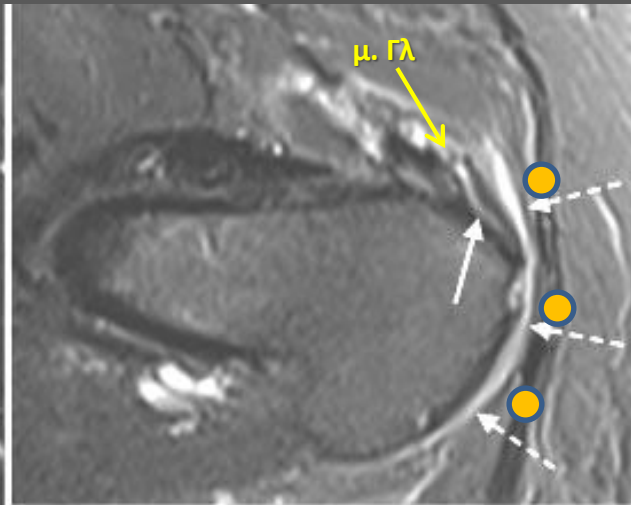
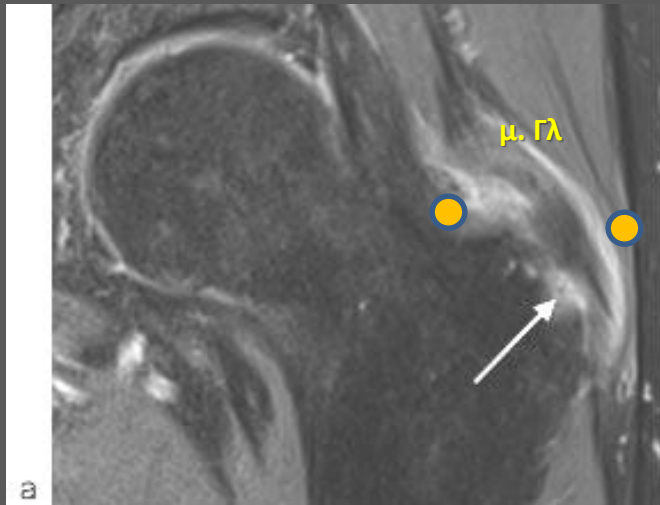
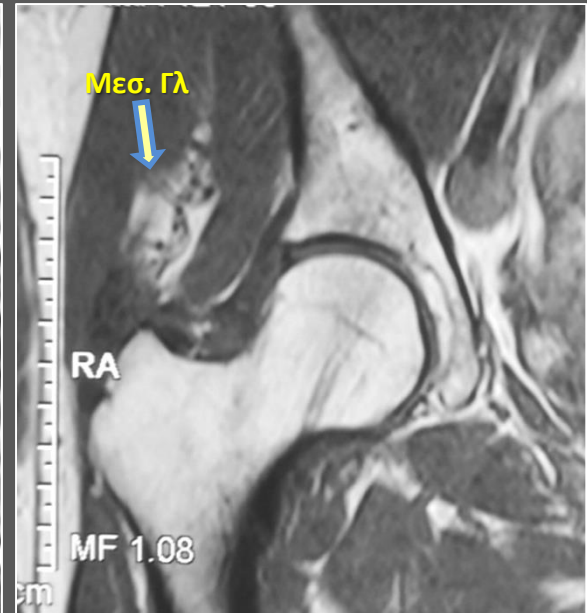
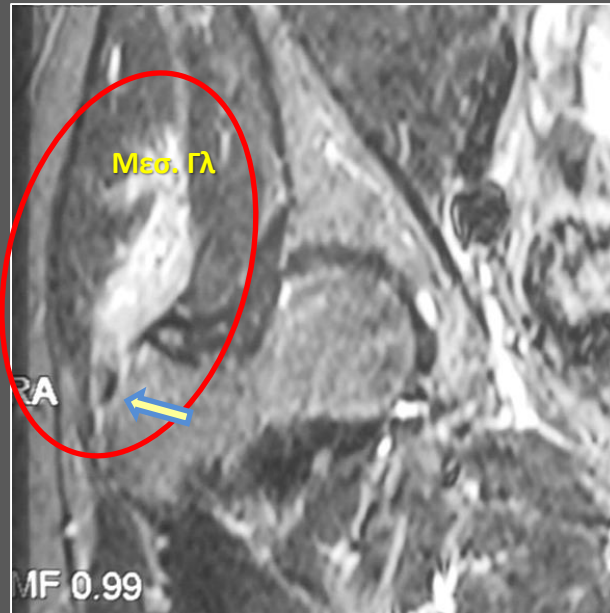
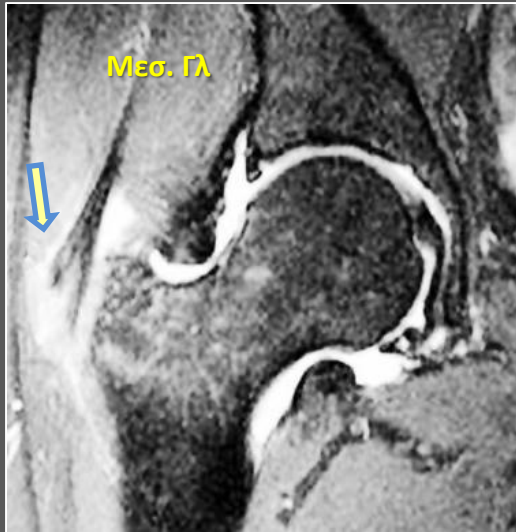




MRI Ευαισθησία: 91-95%  
Ειδικότητα: 70%

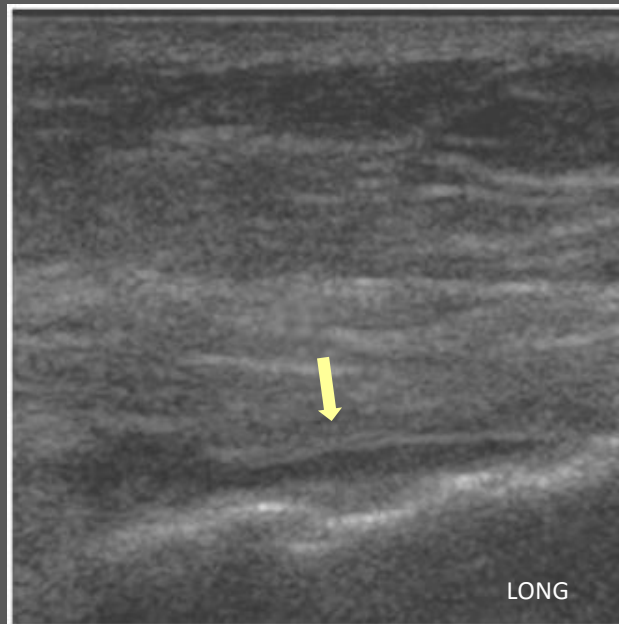
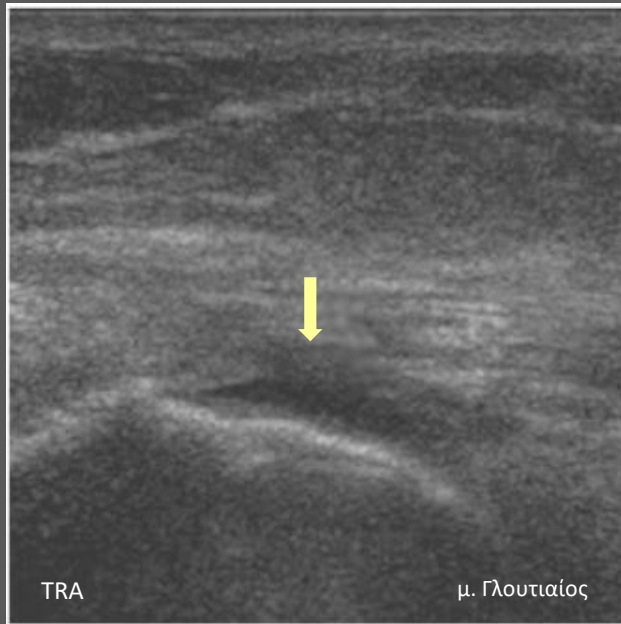
# Τενόντια Ρήξη

≈22% σε ηλικιωμένους

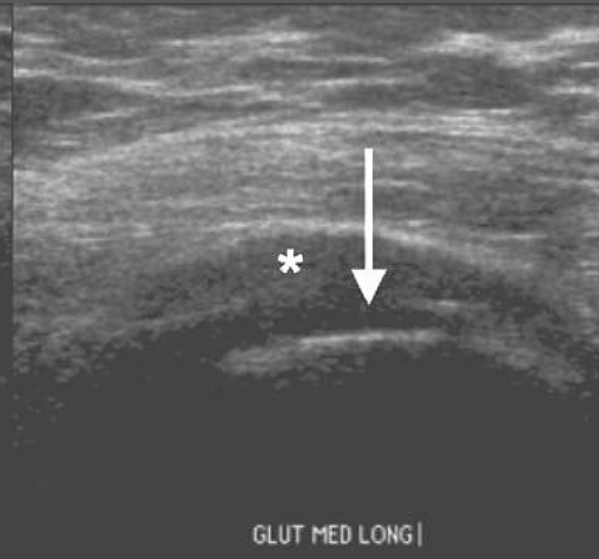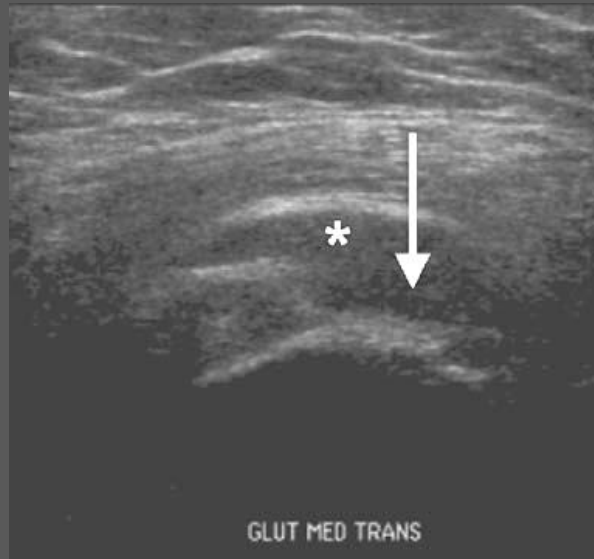


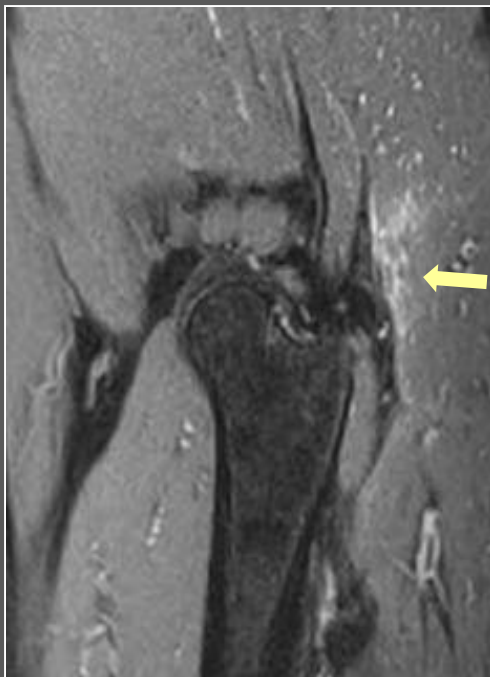# Τενόντια Ρήξη

“bold” facet

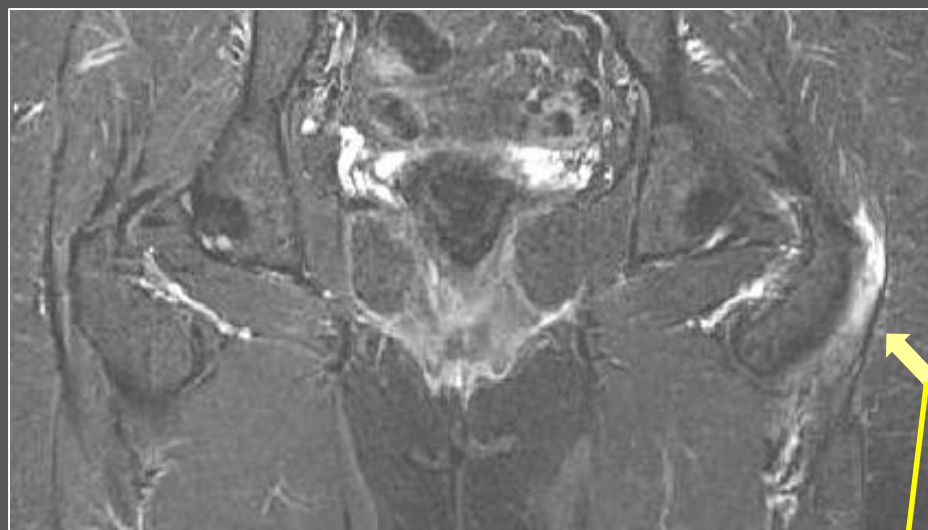
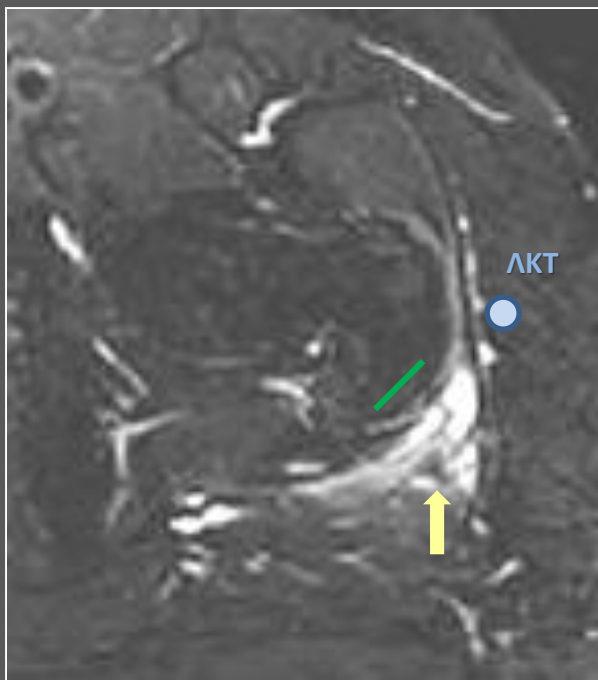
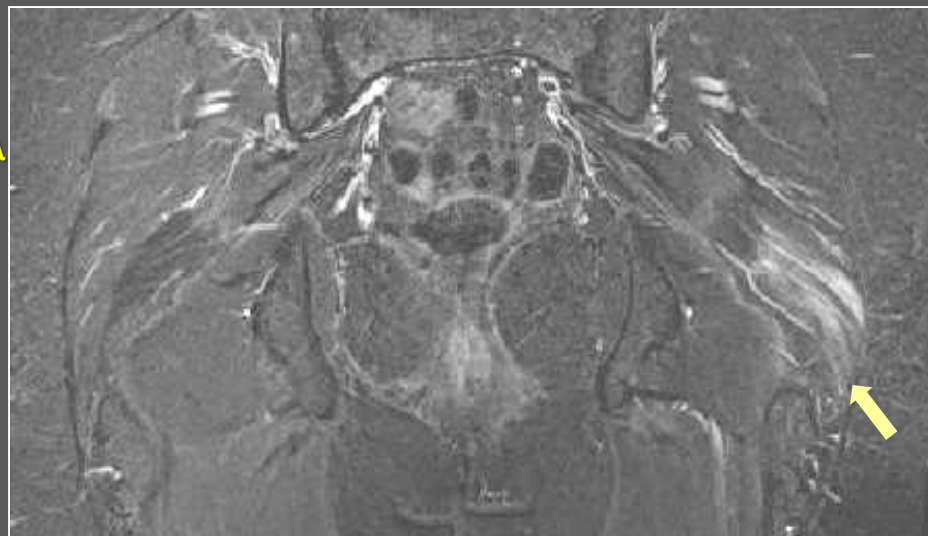


Λέπτυνση του τένοντα ,  
μερικού ή ολικού πάχους  
ανηχωγενή ενδοτενόντια  
ελλείματα



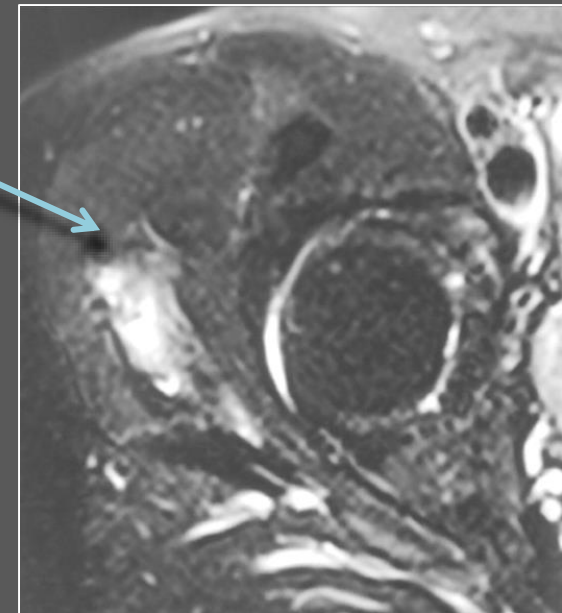
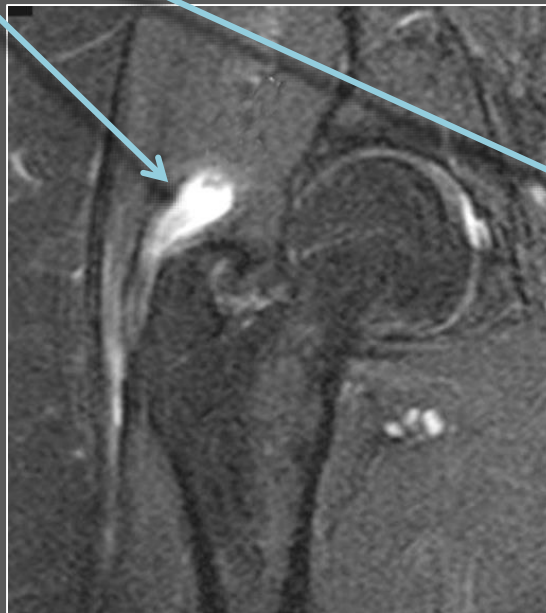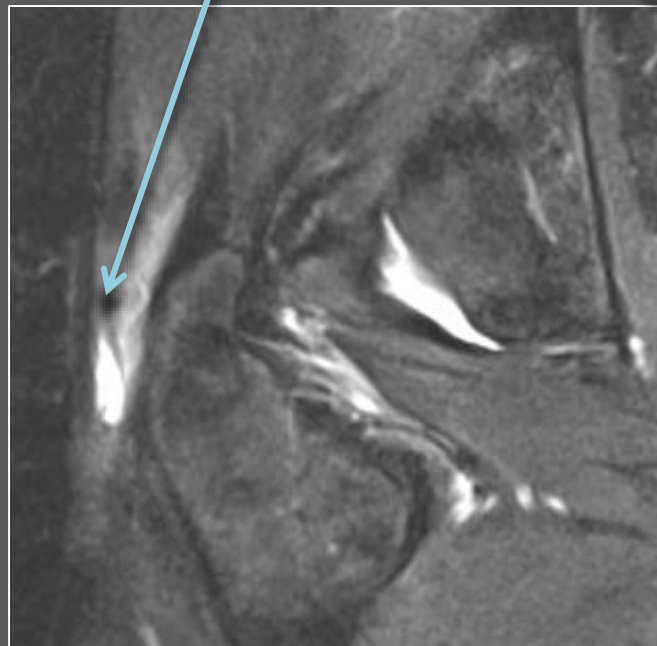
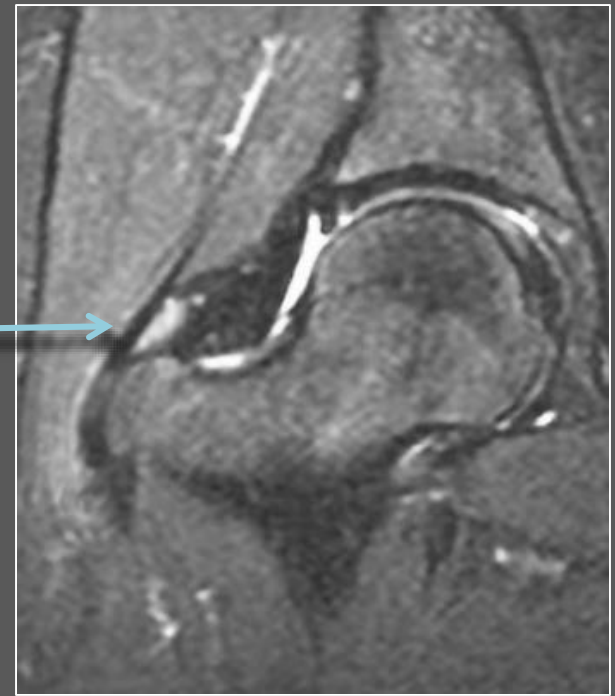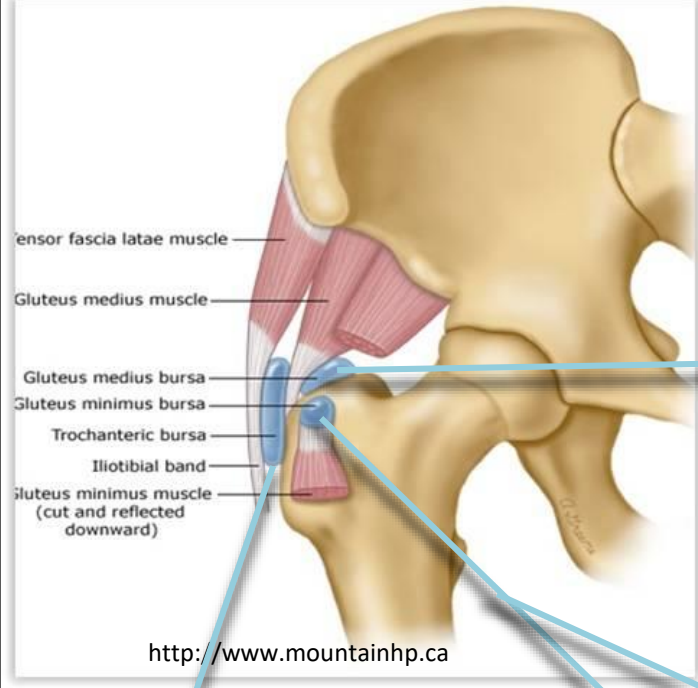


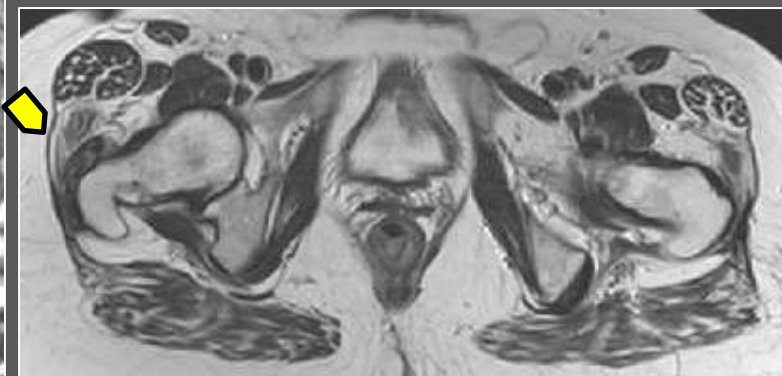
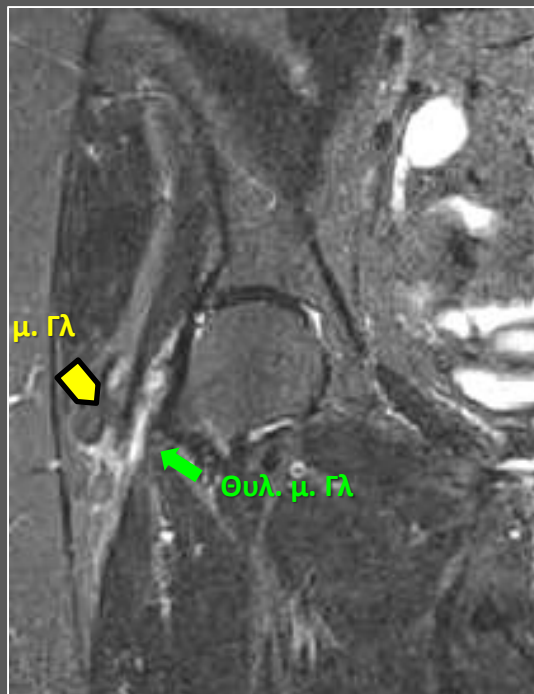
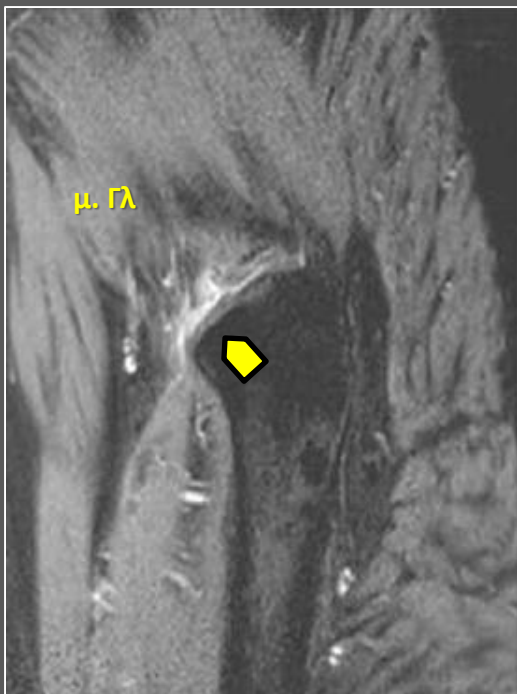
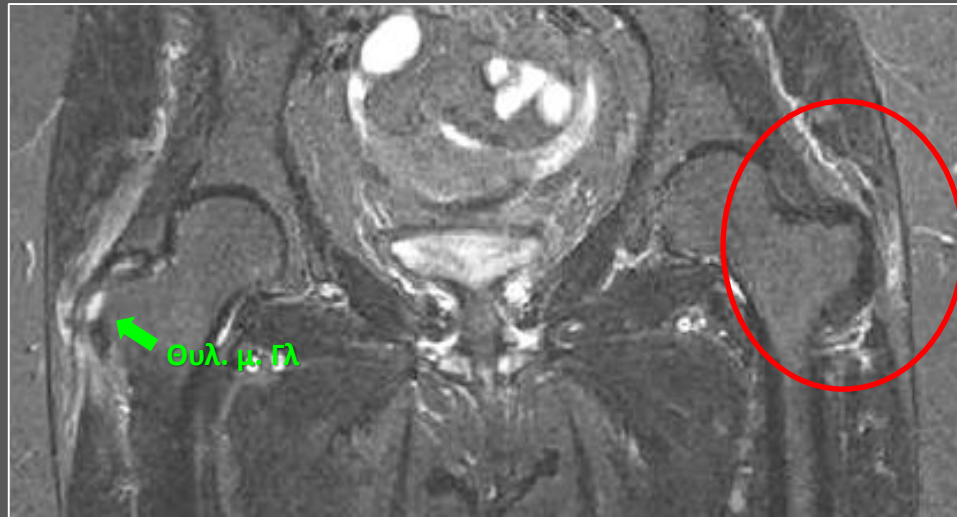
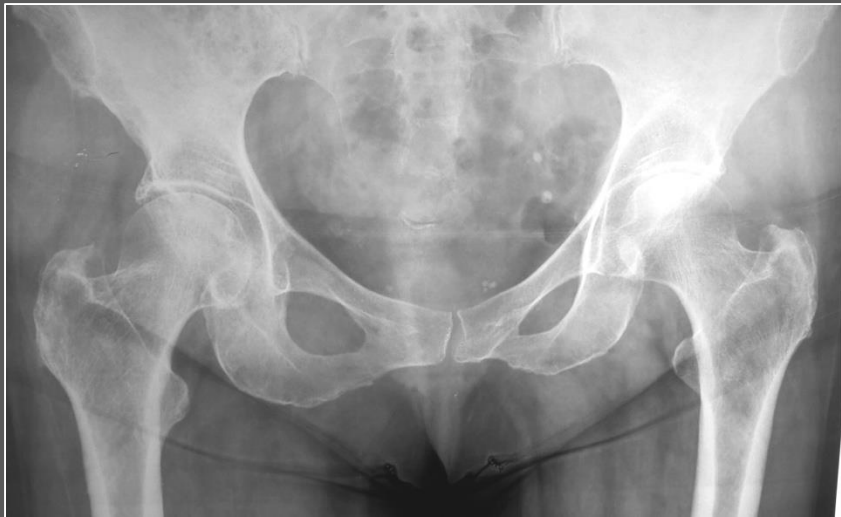Μεσ. Γλ



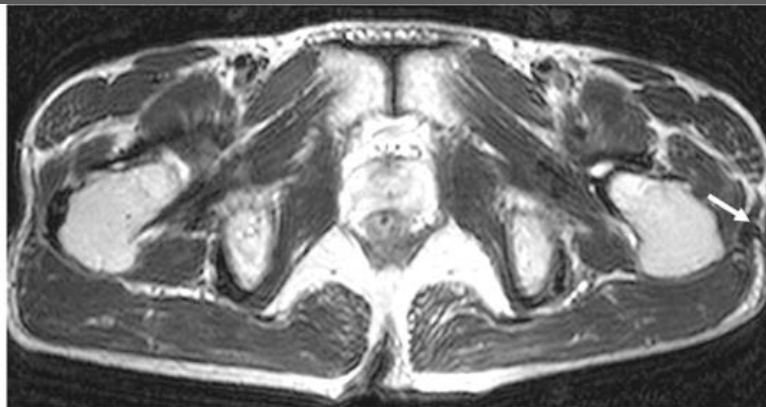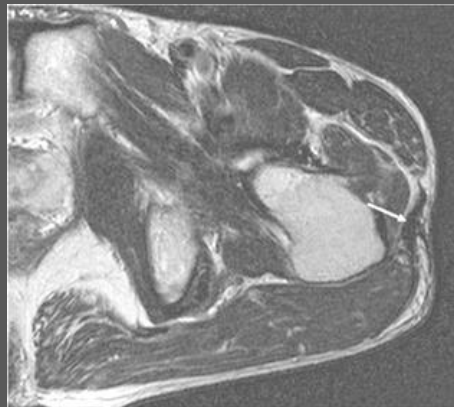
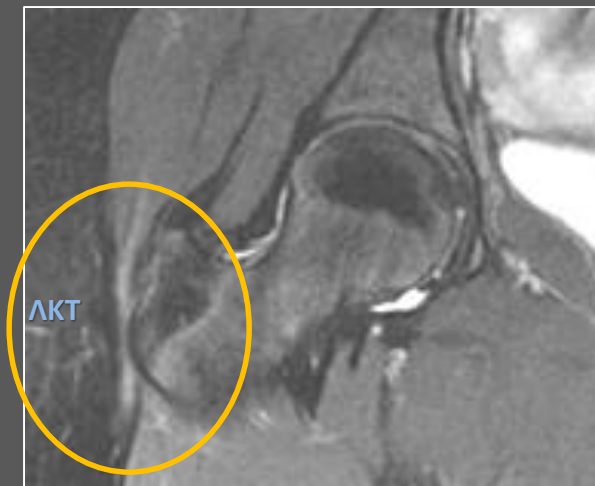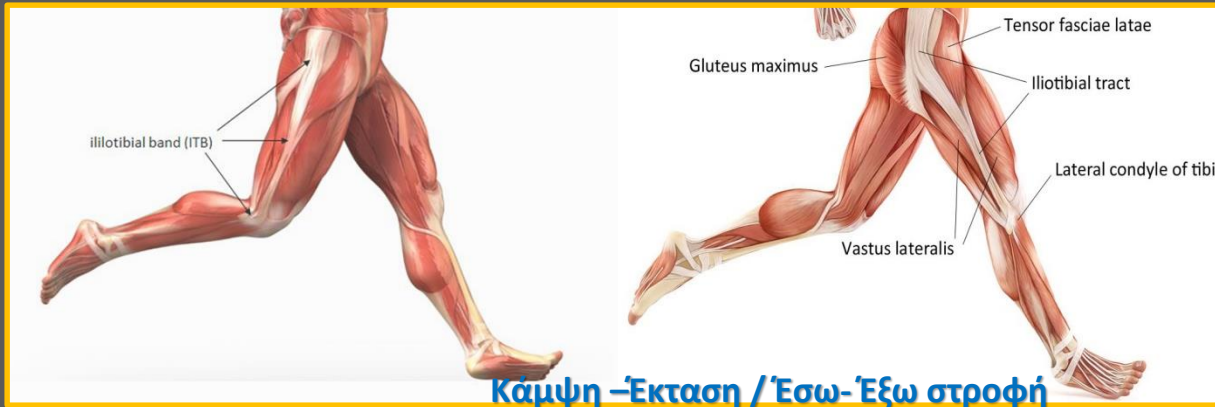Θυλακίτις του Μειζ. Τροχ. Στο 20% ΣΕΜΤ

# Θυλακίτις





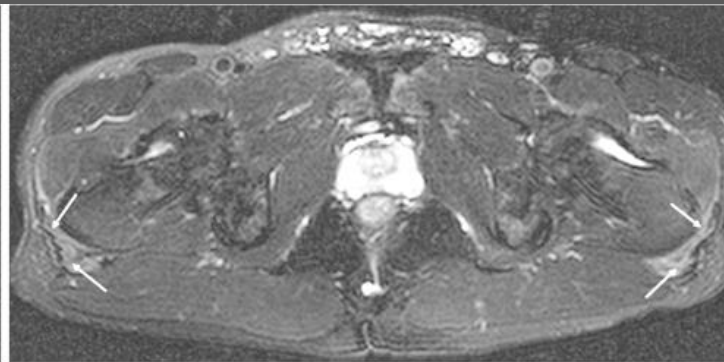
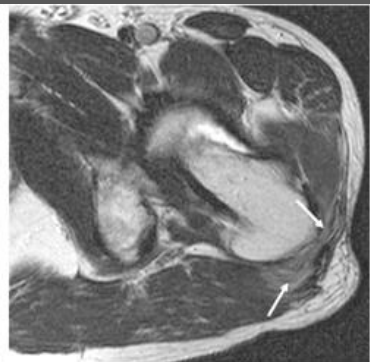
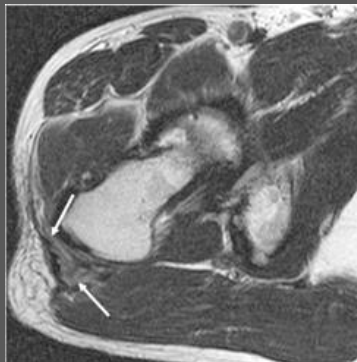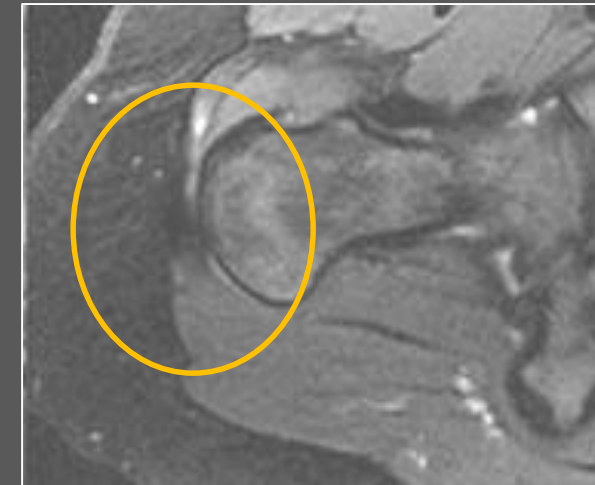
# Λαγονοκνημιαία ταινία / coxa saltans



A

B

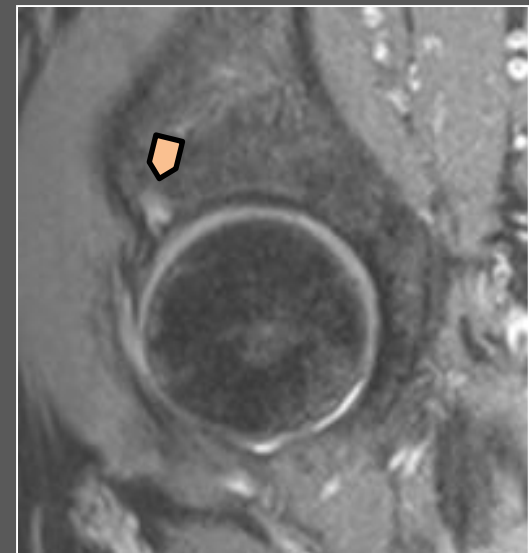
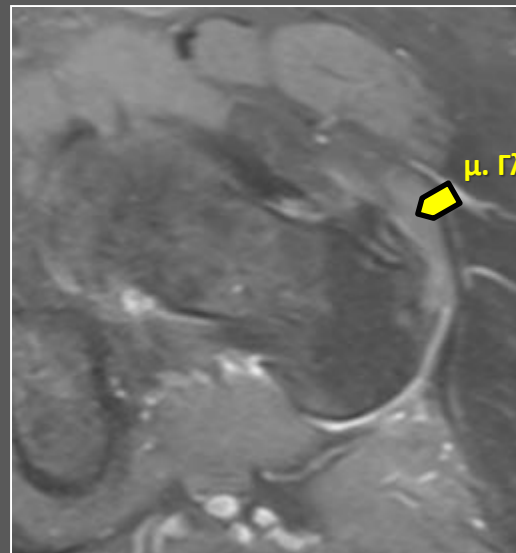
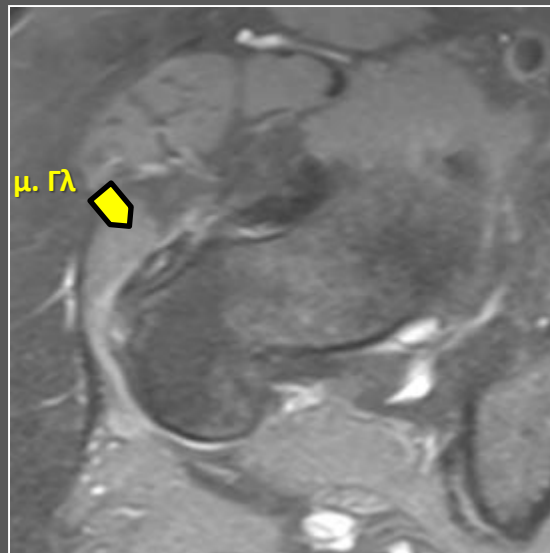
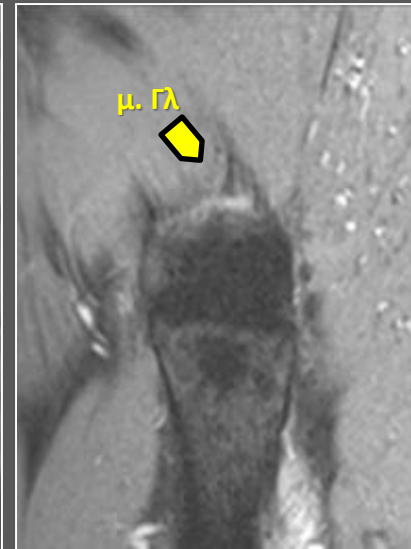
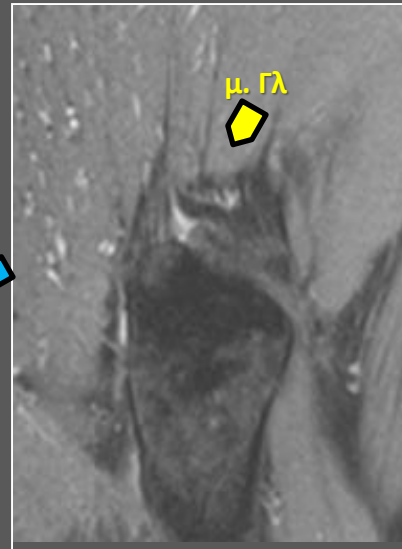
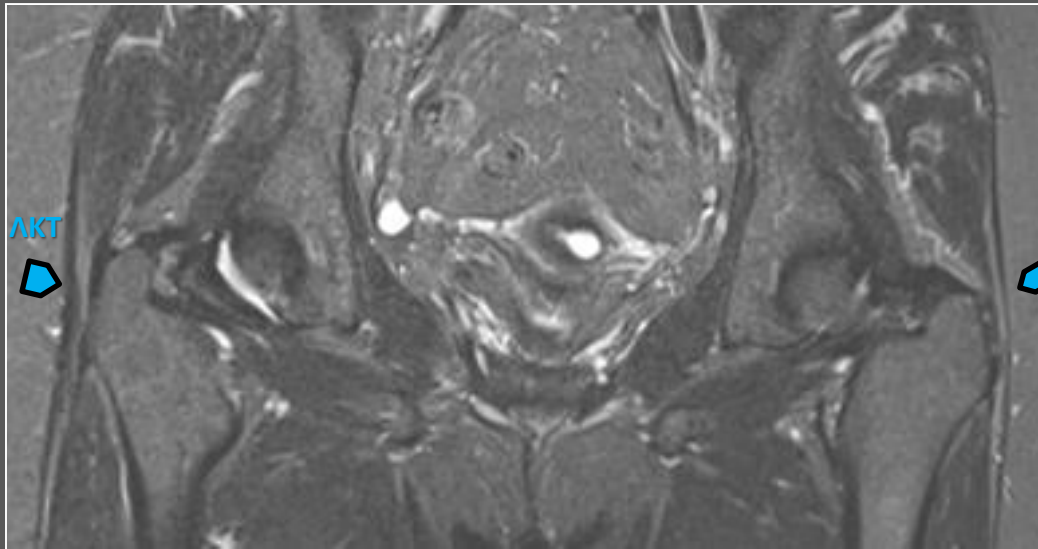
Jung Eun Choi, et al. J Korean Soc Radiol. 2010 Feb;62(2):185-190



A

B

♀ 66 χρ «Τροχαντηρίτις» άμφω ανθεκτική στη συντηρητική θεραπεία



# Θεραπεία (με απεικονιστική καθοδήγηση)

Coombes BK, Bisset L, Vicenzino B.

Efficacy and safety of corticosteroid injections and other injections for management of tendinopathy: a systematic review of randomised controlled trials. Lancet. 2010;376:1751–1767.

...There is a low rate of serious adverse effects after CSI, while minor side effects such as skin depigmentation and post injection pain are common

Brinks A, van Rijn RM, Willemsen SP, Bohnen AM, Verhaar JA, Koes BW, et al.

Corticosteroid injections for greater trochanteric pain syndrome: a randomized controlled trial in primary care. Ann Fam Med. 2011; 9(3):226-34.

...a clinically relevant effect was shown at 3 months for recovery and for pain at rest and with activity: the recovery rate was 34% in the usual care group and 55% in the injection group. However, at 12 months, the differences in outcome were no longer present: the recovery rate was 60% in the usual care group and 61% in the injection group.

Park KD, Lee WY, Lee J, Park MH, Ahn JK, Park Y.

Factors Associated with the Outcome of Ultrasound-Guided Trochanteric Bursa Injection in Greater Trochanteric Pain Syndrome: A Retrospective Cohort Study. Pain Physician 2016;19 (4):E547-57.

...in GTPS patients treated with ultrasonographically guided injections of corticosteroids and local anesthetics, the presence of knee osteoarthritis, lumbar facet joint pain, or sacroiliac joint pain may reduce the therapy's effectiveness

Kaux JF, Forthomme B, Le Goff C, Crielaard JM, Croisier JL.

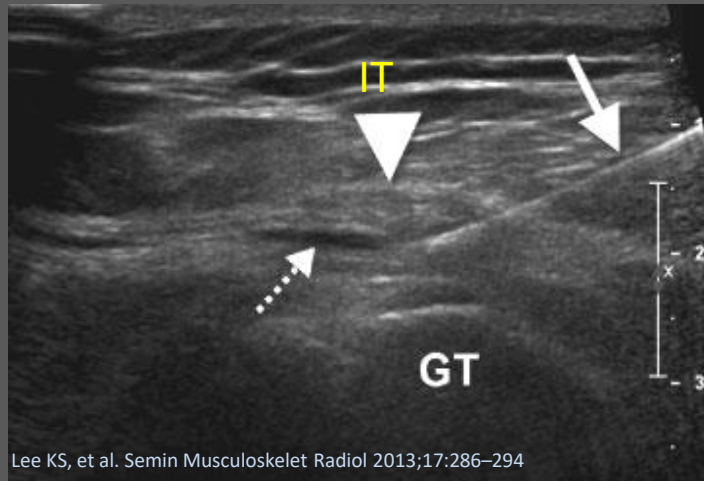
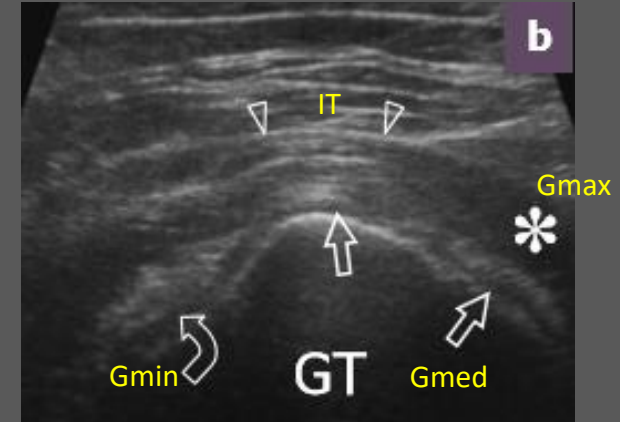
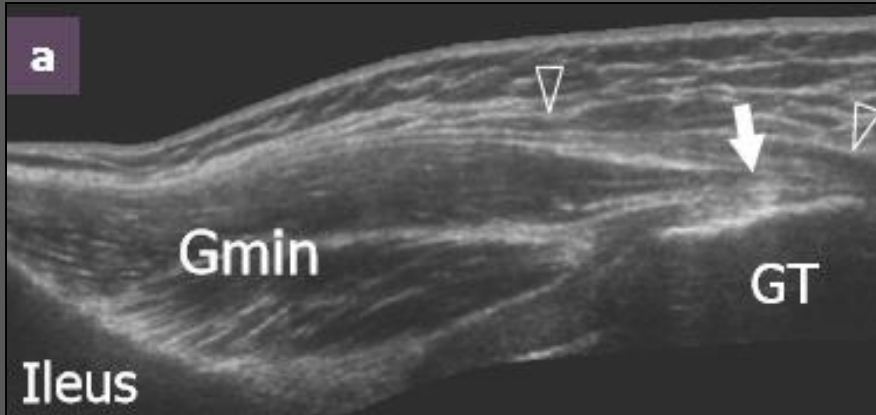

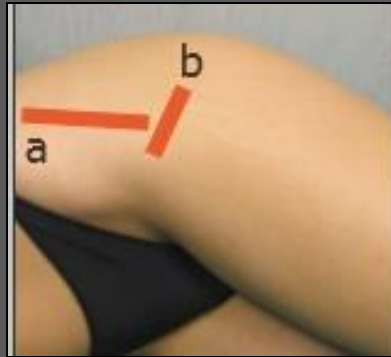
Current opinions on tendinopathy. J Sports Sci Med. 2011;10:238–253.

...CSI may be most appropriately used to reduce pain which would enable physiotherapy to be most effective

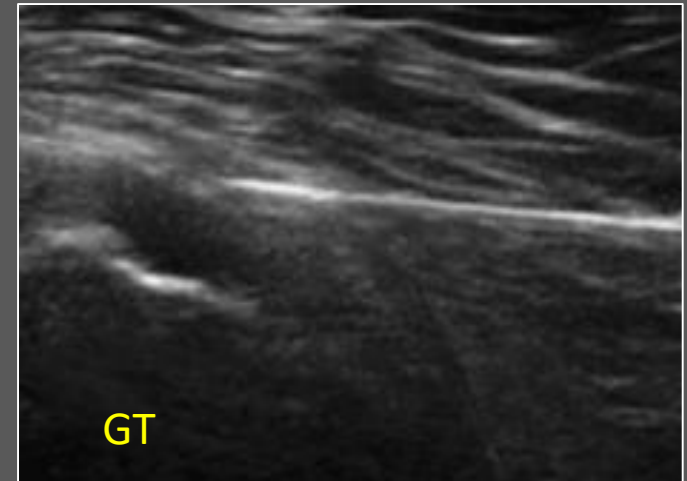

# Θεραπεία (με απεικονιστική καθοδήγηση)

40 -80mg triamcinolone /  
methylprednisolone  
2-5 mL of 1% lidocaine



Lee KS, et al. Semin Musculoskelet Radiol 2013;17:286-294






- ΟΣΤΕΟΑΡΘΡΙΤΙΣ ΤΟΥ ΙΣΧΙΟΥ
- ΚΑΤΑΓΜΑΤΑ ΚΟΠΩΣΕΩΣ / ΑΝΕΠΑΡΚΕΙΑΣ ΤΟΥ ΙΣΧΙΟΥ
- ΝΕΥΡΟΠΑΘΕΙΑ ΤΟΥ ΑΝΩ ΓΛΟΥΤΙΑΙΟΥ ΝΕΥΡΟΥ
- ΣΠΟΝΔΥΛΟΑΡΘΡΟΠΑΘΕΙΑ / ΡΕΥΜΑΤΙΚΗ ΠΟΛΥΜΥΑΛΓΙΑ
- ΕΚΦΥΛΙΣΤΙΚΕΣ ΑΛΛΟΙΩΣΕΙΣ ΤΗΣ ΟΜΣΣ / ΙΕΡΟΚΑΛΟΝΙΩΝ ΑΡΘΡΩΣΕΩΝ

European Spine Journal  
1 February 2018, Pages 1-8

## Great trochanter bursitis vs sciatica, a diagnostic–anatomic trap: differential diagnosis and brief review of the literature

Zibis, A.H., Mitrousias, V.D., Klontzas, M.E., Karachalios, T., Varitimidis, S.E., Karantanas, A.H., Arvanitis, D.L. 

### Abstract

**Purpose:** The purpose of this study is to point out the difficulty of differentiating great trochanter bursitis (GTB) from sciatica and estimating the prevalence of GTB, in patients poorly diagnosed with sciatica in their first visit to the general practitioner and referred to a spine infirmary. **Methods:** The diagnosis of GTB was made based on history and physical examination, and was confirmed by ultrasonography and/or response to an anesthetic plus corticosteroid injection to the trochanteric bursa. Demographic and clinical characteristics of the study group were evaluated. The statistical analysis was held with the SPSS pc package (version 24.0). **Results:** In a total of 657 referrals for sciatica, 72 patients (10.95%) were incorrectly diagnosed as suffering from sciatica, whereas, in fact, they were suffering from GTB. In addition, 18 patients (2.74%) were diagnosed as suffering from persistent sciatica with coexisting GTB. More

Skeletal Radiol. 2015 Dec;44(12):1727-33. doi: 10.1007/s00256-015-2220-7. Epub 2015 Aug 11.

**Prevalence and pattern of gluteus medius and minimus tendon pathology and muscle atrophy in older individuals using MRI.**

Chi AS<sup>1</sup>, Long SS<sup>2</sup>, Zoga AC<sup>3</sup>, Read PJ<sup>4</sup>, Deely DM<sup>5</sup>, Parker L<sup>6</sup>, Morrison WB<sup>7</sup>

### CONCLUSIONS:

Gluteus medius and minimus tendon pathology and muscle atrophy increase with advancing age with progression of tendinosis to low-grade tendon tears to high-grade tendon tears. There is an associated progression in atrophy of these muscles, which may be important in fall-related hip fractures.

Hirschmann A. et al. Semin Musculoskelet Radiol 2017;21:539–546

Kong A, et al. Eur Radiol 2007;17: 1772–1783

Jung Eun Choi, et al. J Korean Soc Radiol 2010 Feb;62(2):185-190

Ik Yang et al. Skeletal Radiol 2002;31:359–361

Kaltenborn A, et al. PLoS ONE 9(3): e91560. doi:10.1371/journal.pone.0091560

Reid D. Journal of Orthopaedics 2016;13:15-28

Long SS, et al. Am J Roentgenol. 2013;201:1083–1086.

Klauser AS, et al. Semin Musculoskelet Radiol. 2013;17:43–48

Moulton KM, et al. Skelet Radiol. 2014;44:47–54.

Bird PA, et al. Arthritis Rheum. 2001;44:2138–2145

Klontzas ME , et al. Eur J Radiol. 2014;83(10):1850-5

Steinert L, et al. Radiology. 2010;257(3):754-63

Blankenbaker DG , et al. Skeletal Radiol. 2008;37(10):903-9

Cvitanic O, et al. AJR 2004;182:137–143

Connell D, et al. Eur Radiol 2003;13:1339–1347

