

Συχνές ρευματολογικές παθήσεις

Black and white, X-Rays

Απόστολος Καραντάνας
Πανεπιστήμιο Κρήτης

ΔΙΟΡΓΑΝΩΣΗ
ΠΑΓΚΡΗΤΙΑ
ΕΝΩΣΗ
ΥΓΕΙΑΣ



ΘΕΡΙΝΟ ΣΧΟΛΕΙΟ
ΑΚΤΙΝΟΛΟΓΙΑΣ
ΜΥΟΣΚΕΛΕΤΙΚΟΥ

“BACK TO BASICS”

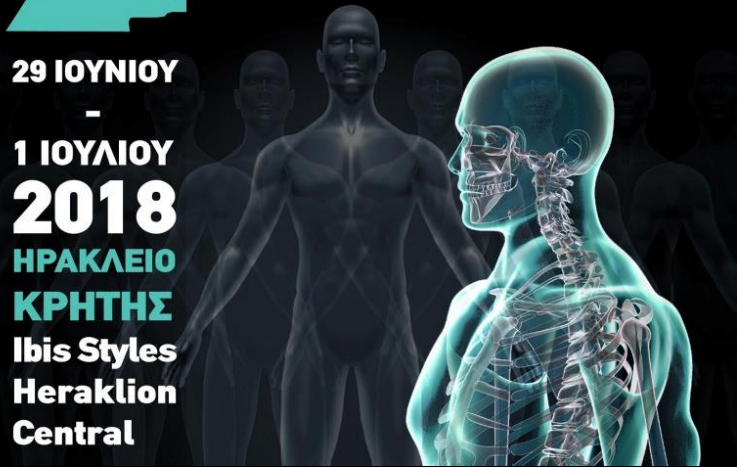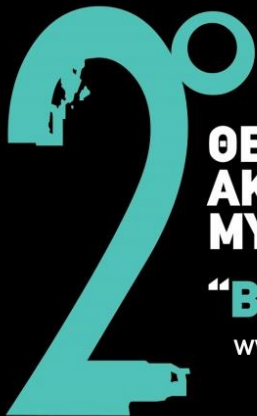www.ssmr-2018.gr

29 ΙΟΥΝΙΟΥ

-

1 ΙΟΥΛΙΟΥ
2018

ΗΡΑΚΛΕΙΟ
ΚΡΗΤΗΣ
Ibis Styles
Heraklion
Central





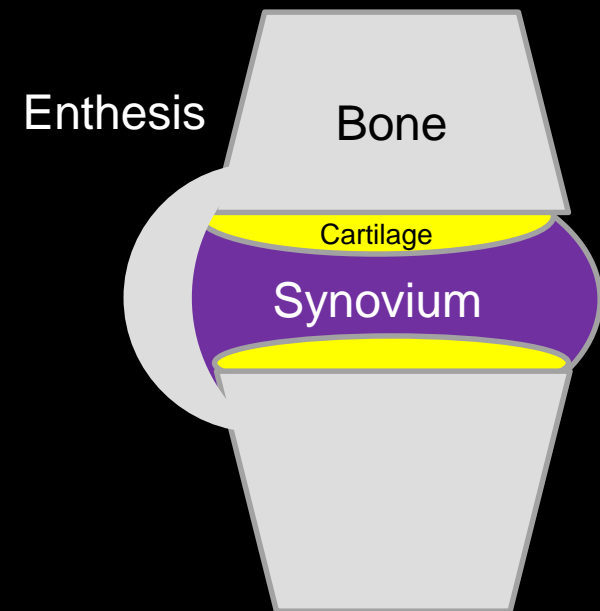
Discriminating features

- Which part of the joint is involved?

Watt I *Basic differential diagnosis of arthritis. Eur Radiol. 1997 7:344–351*

- Target joint approach

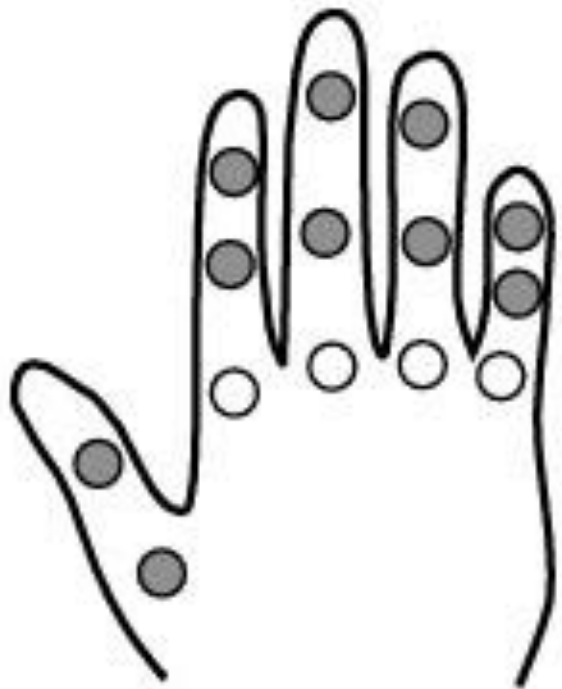Resnick D *Diagnosis of Bone and Joint Disorders*



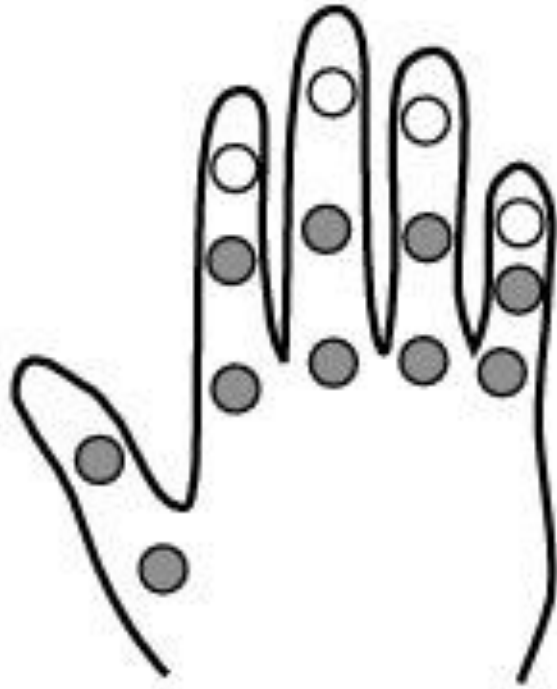Objectives

- Learn the **target joint approach** for Hand Arthritis
- Learn how to recognize features of **AS**
 - New York criteria

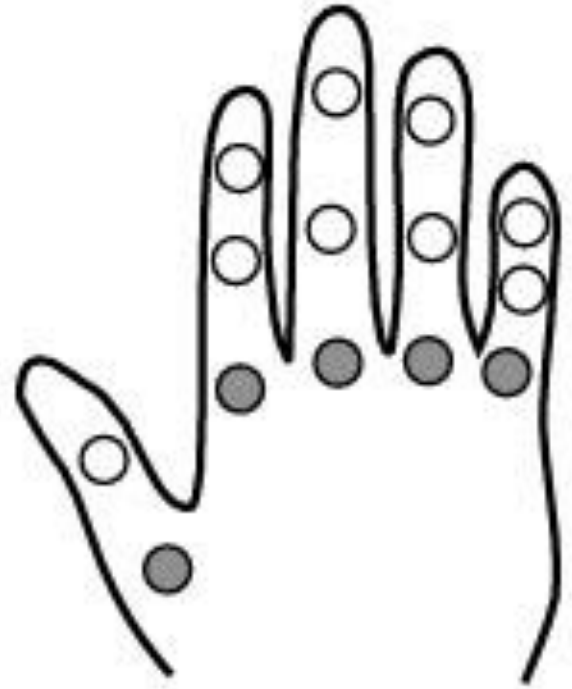The **target joint** approach for Hand Arthritis



OA



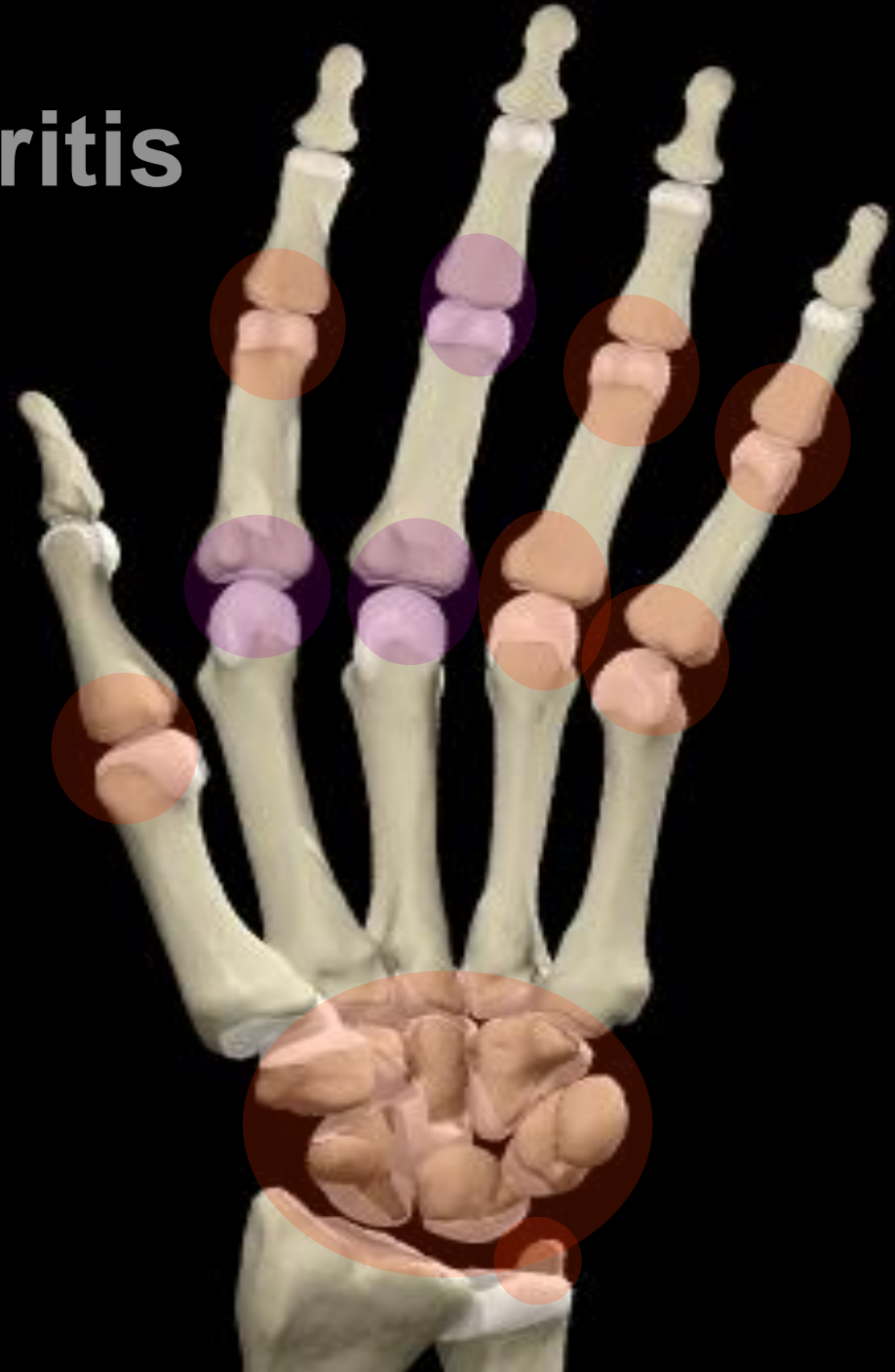RA

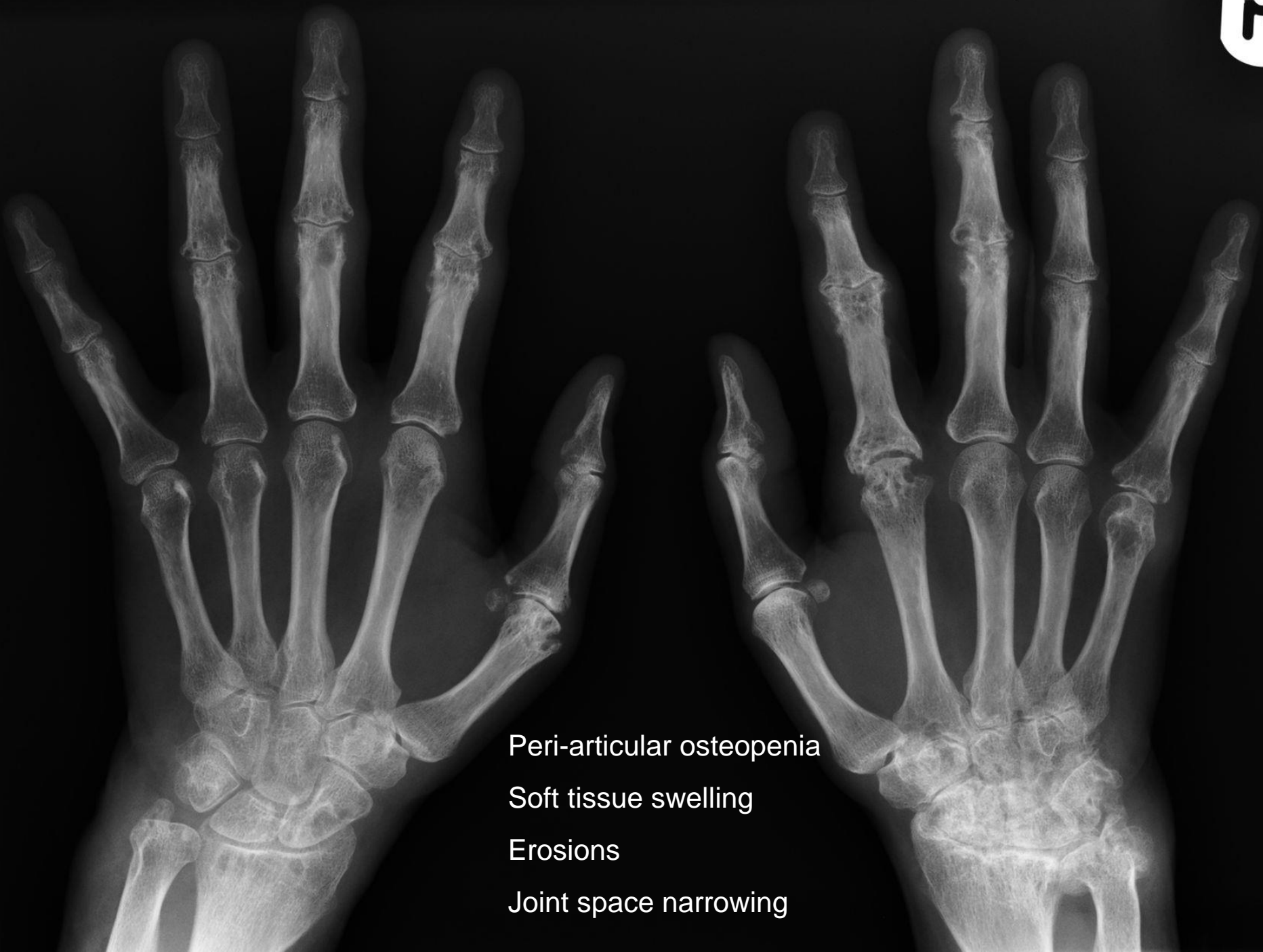

CPPD

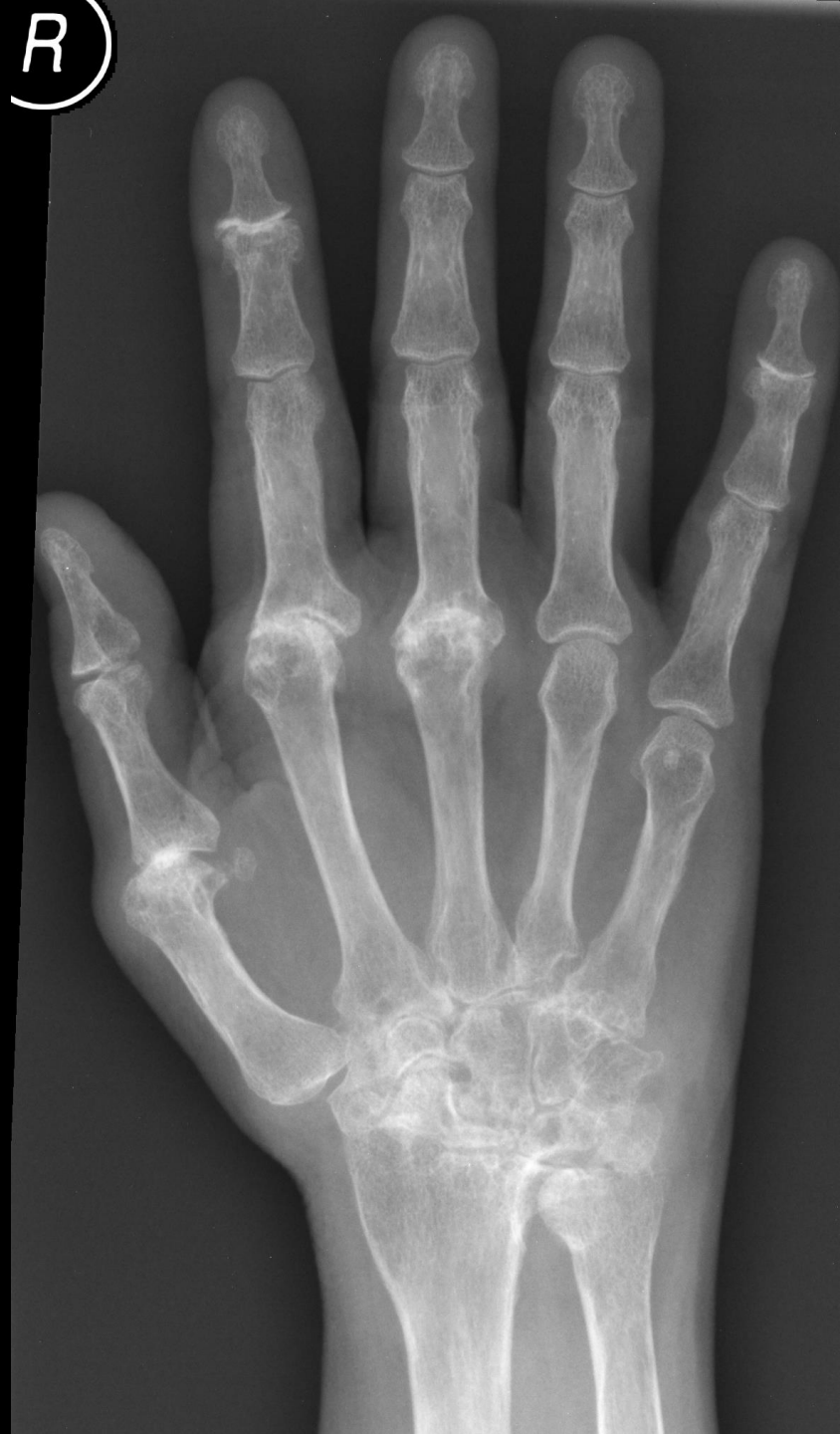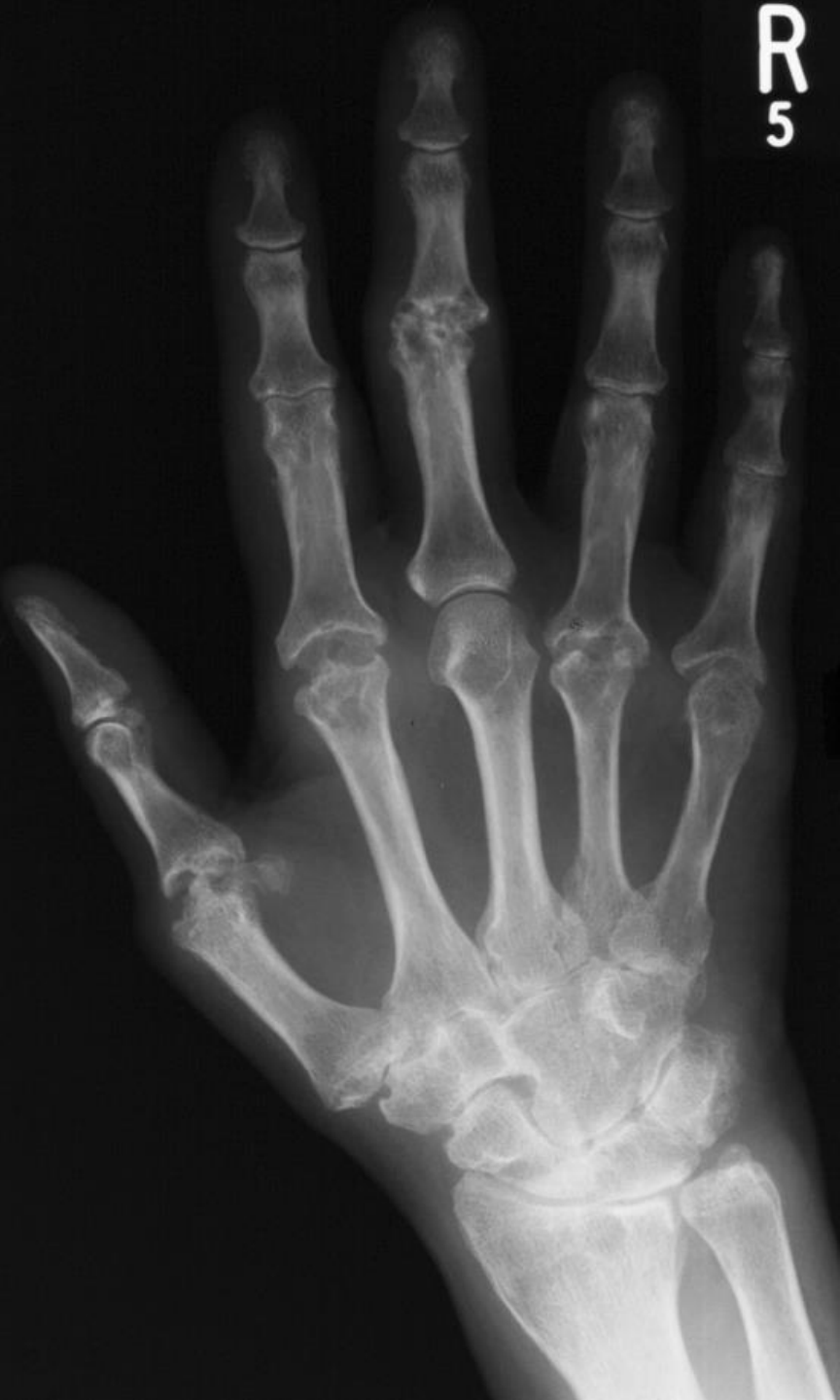Rheumatoid arthritis

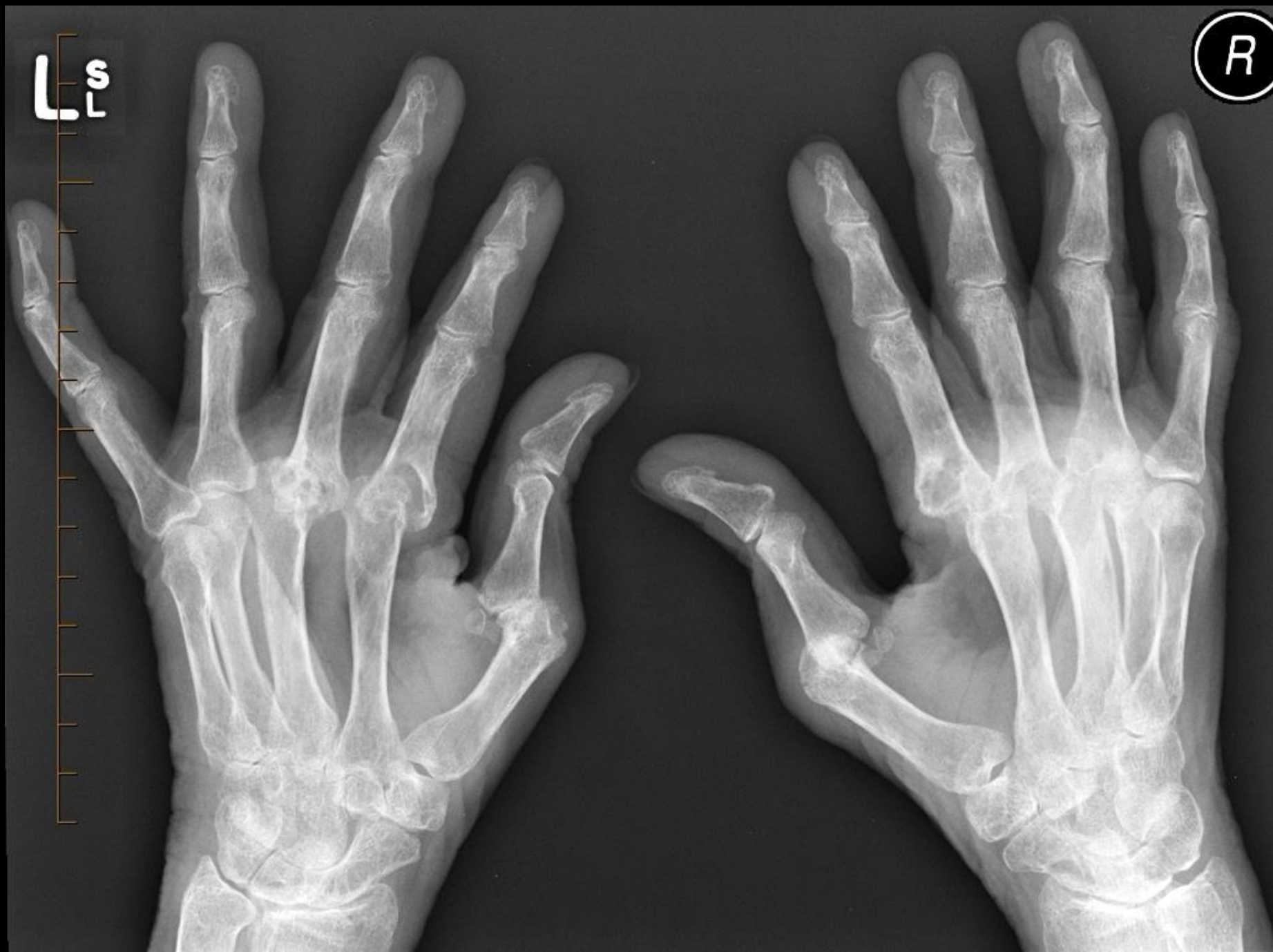- **DIPJ erosions uncommon**
- **3 target joints**
- **radial aspect erosion**





Peri-articular osteopenia
Soft tissue swelling
Erosions
Joint space narrowing





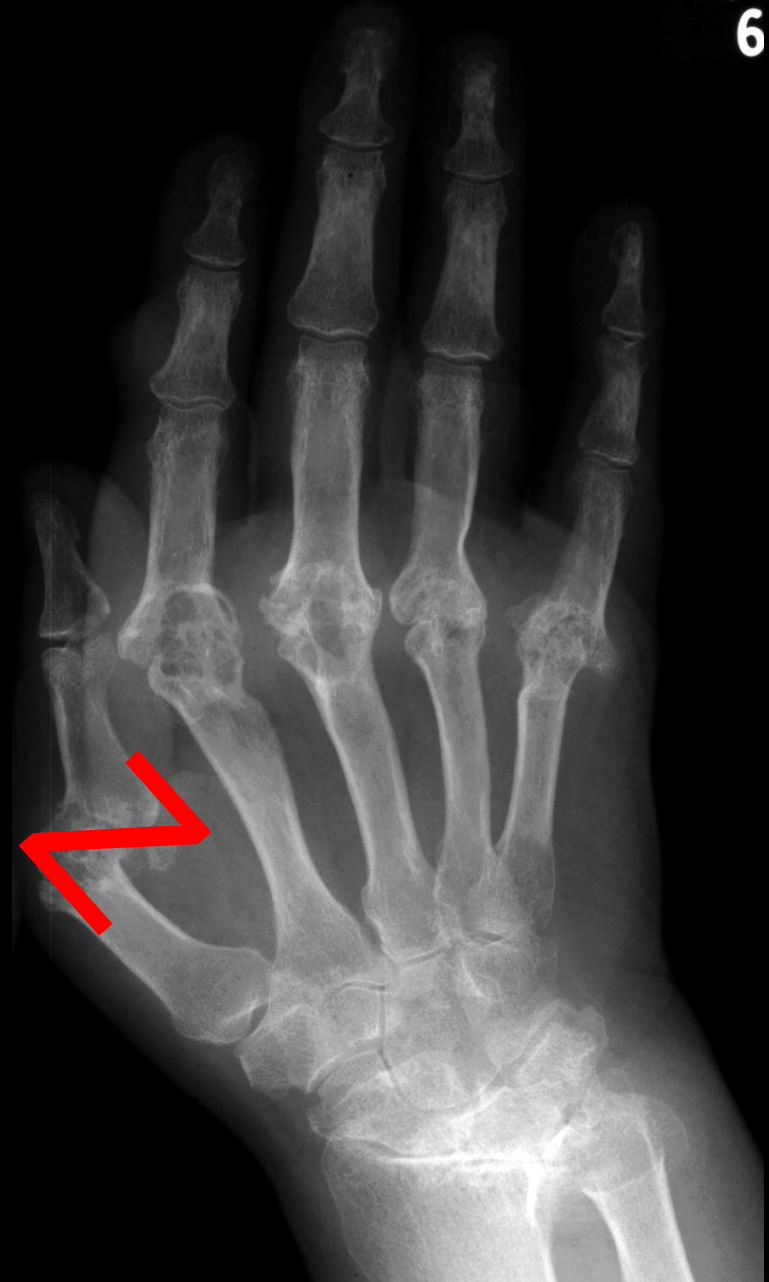RA

6

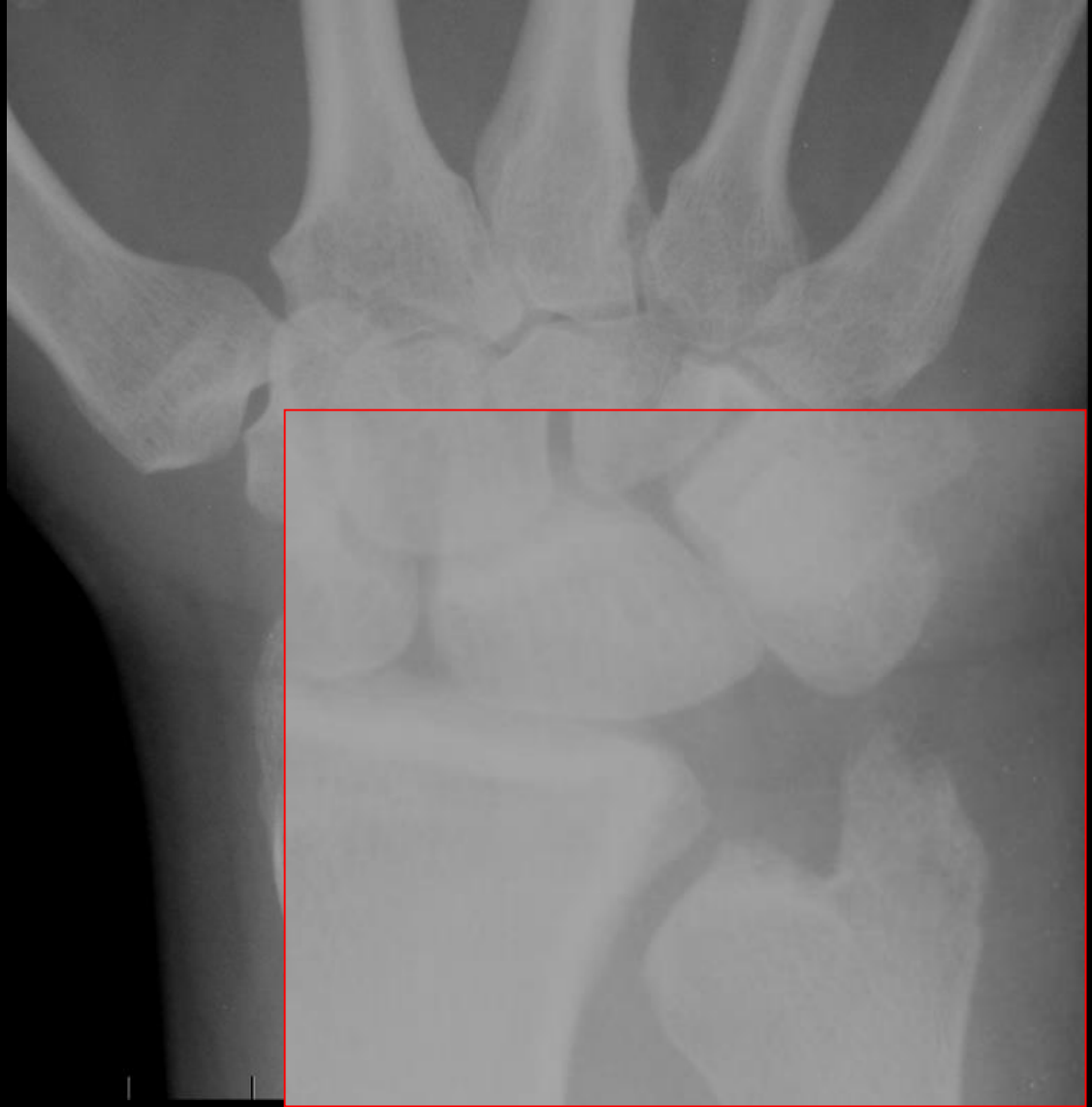
Subluxations

Swan neck and boutonniere

Z thumb

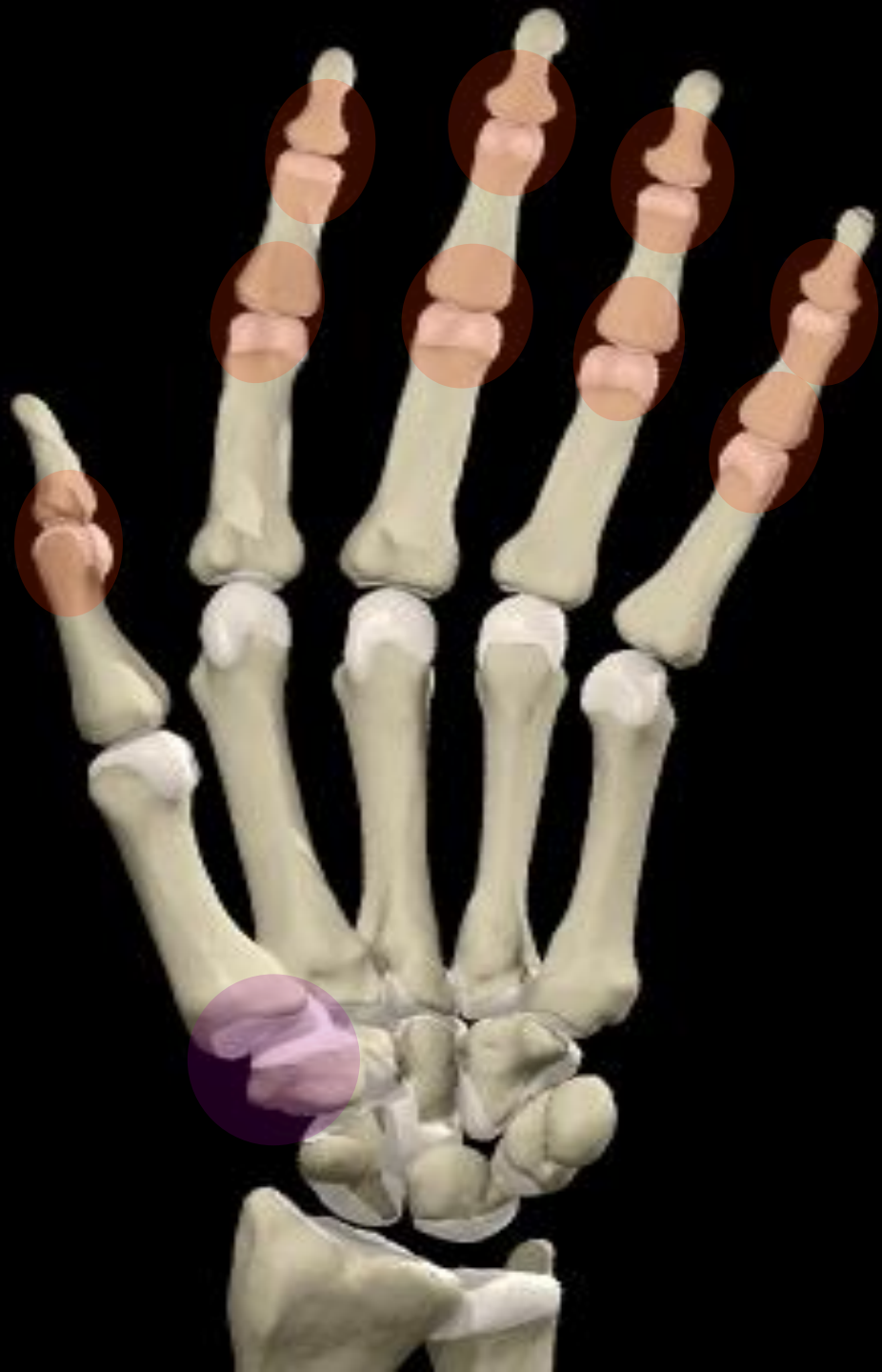

Early involvement RA



Osteoarthritis

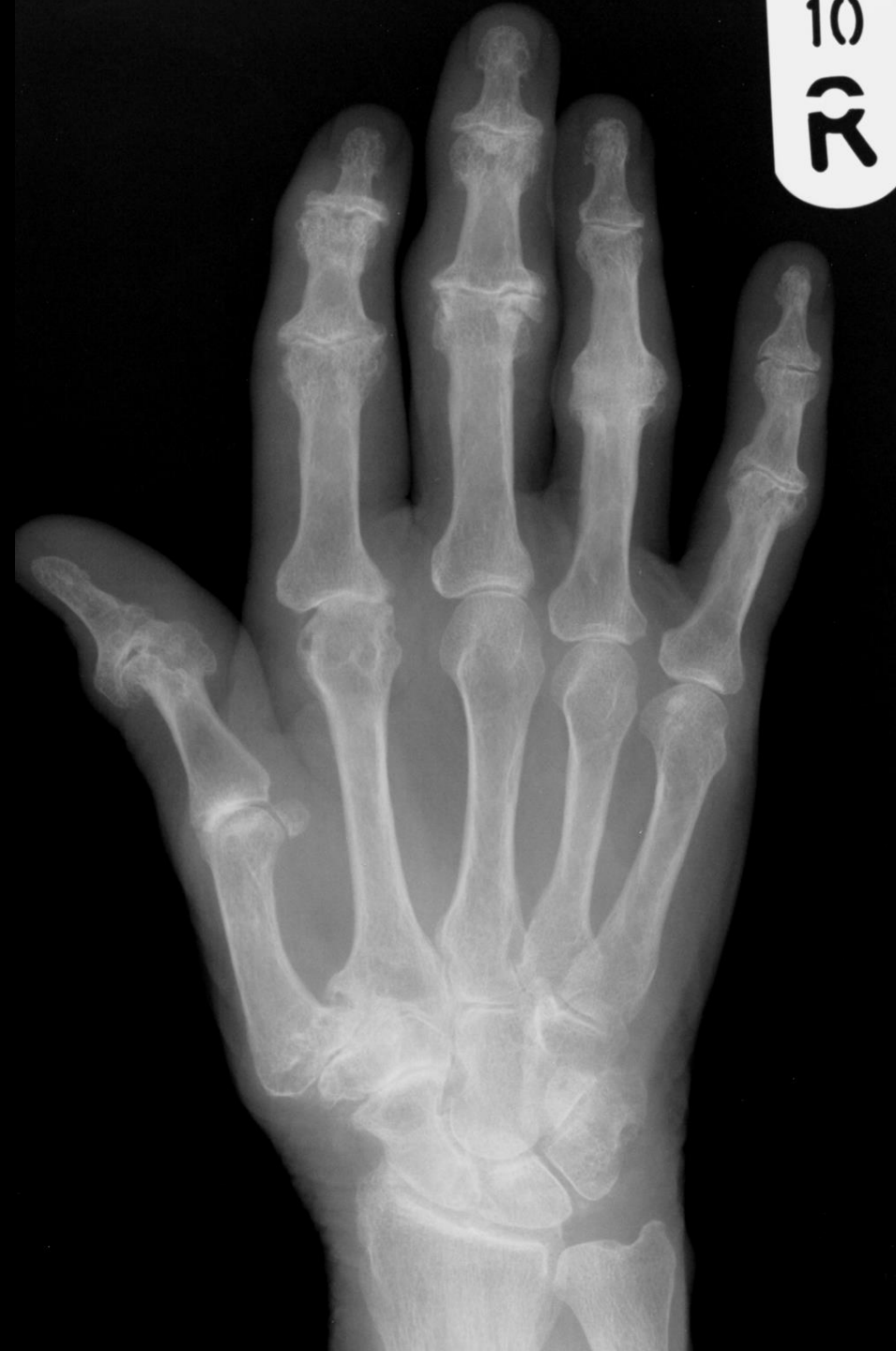PIP and DIP > MCP



OA

Joint space loss

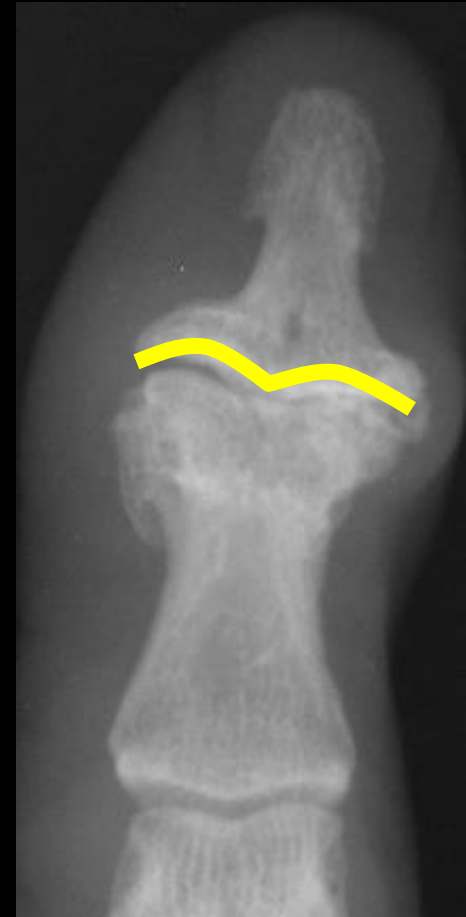Subchondral sclerosis



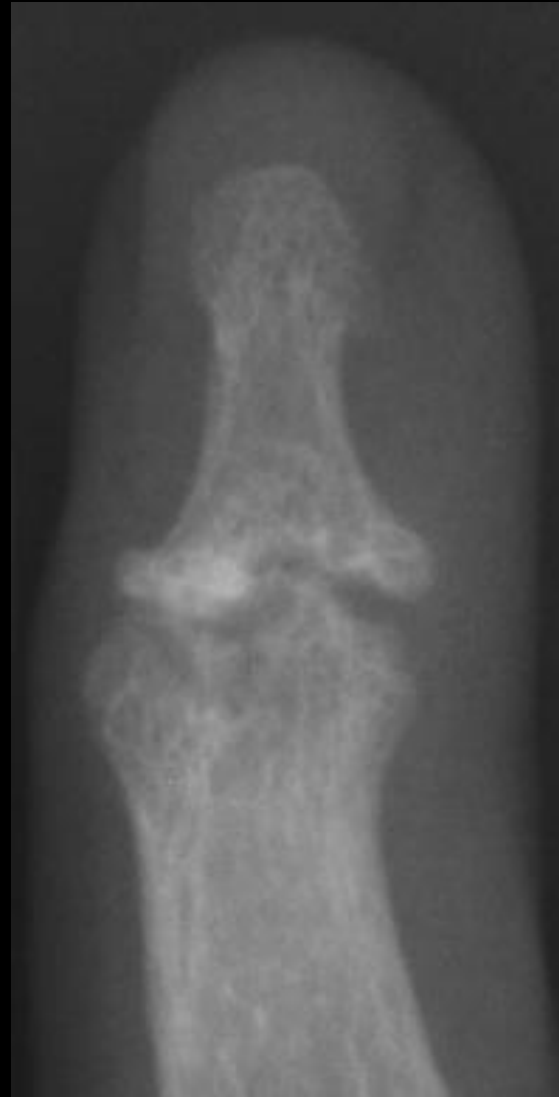

Erosive OA

- Form of OA + erosive/inflammatory component
- Similar distribution to OA
- F:M~12:1, typically postmenopausal, pts.RF (-)
- **Dyslipidemia** may be implicated
- Mimics inflammatory arthropathies: Psa or RA
- Soft tissue swelling, subchondral collapse
- **Gull wing** erosion

Gull wing erosions



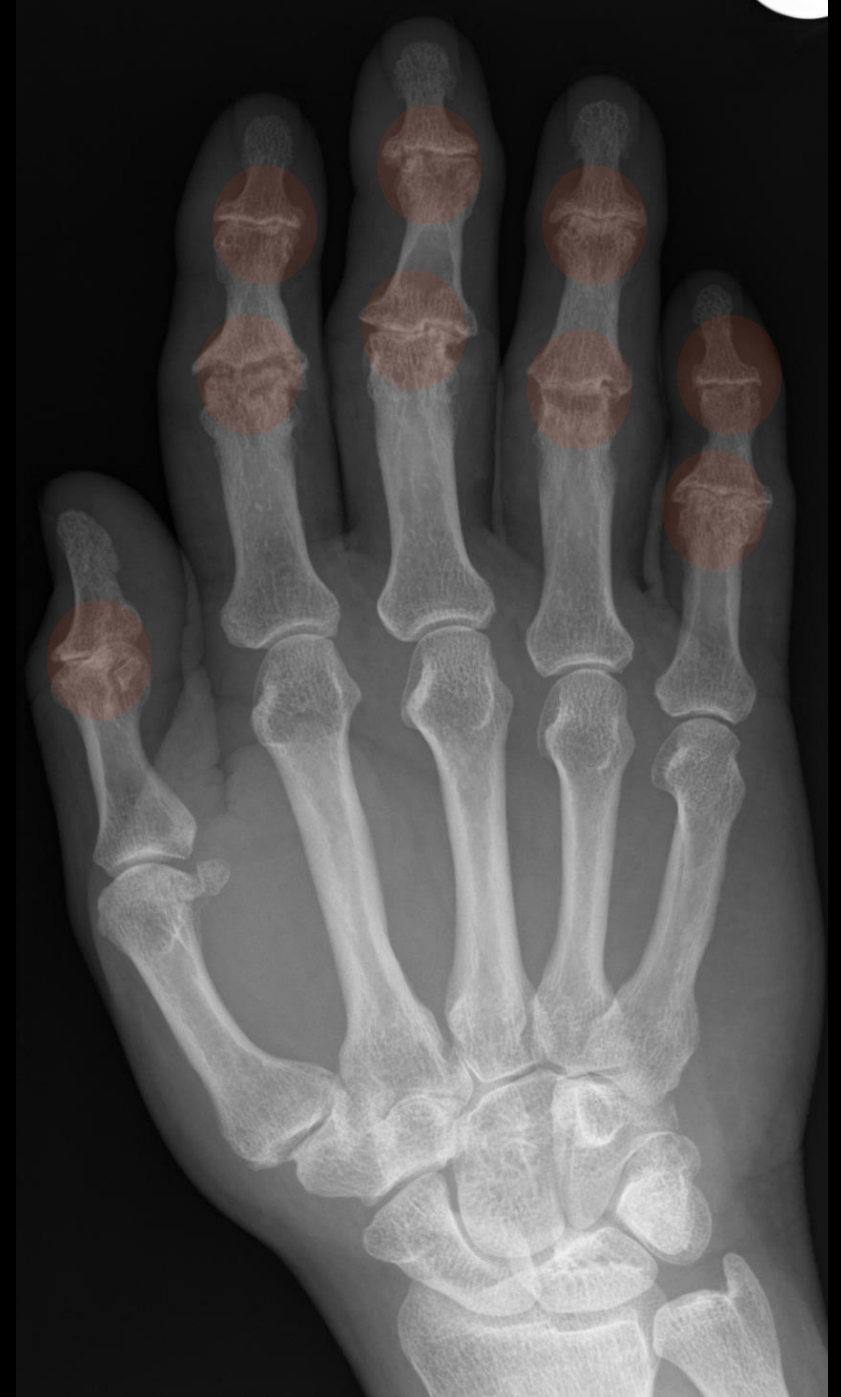Interdigitation



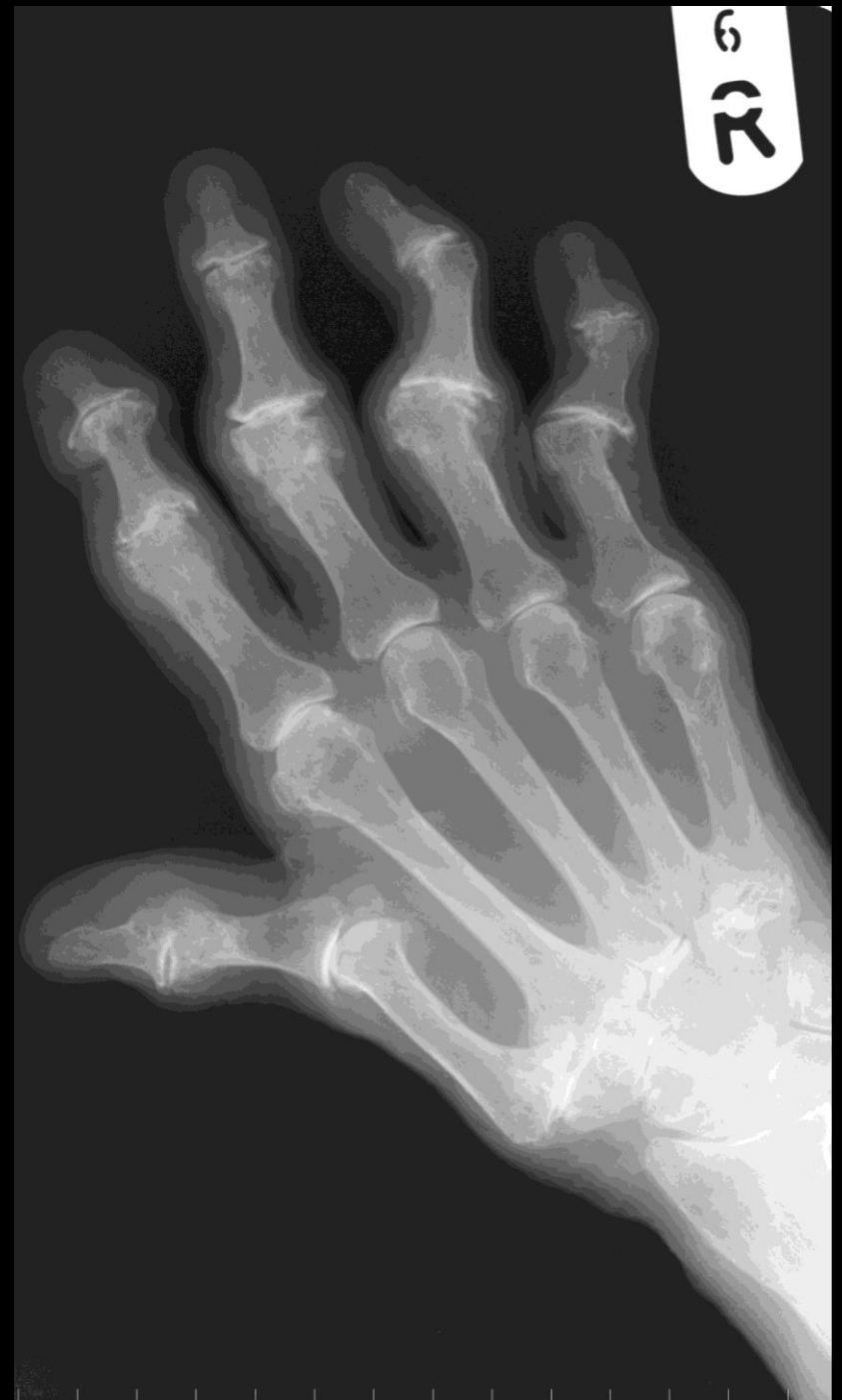Erosive OA

Gull wing erosion

Ankylosis



Erosive OA



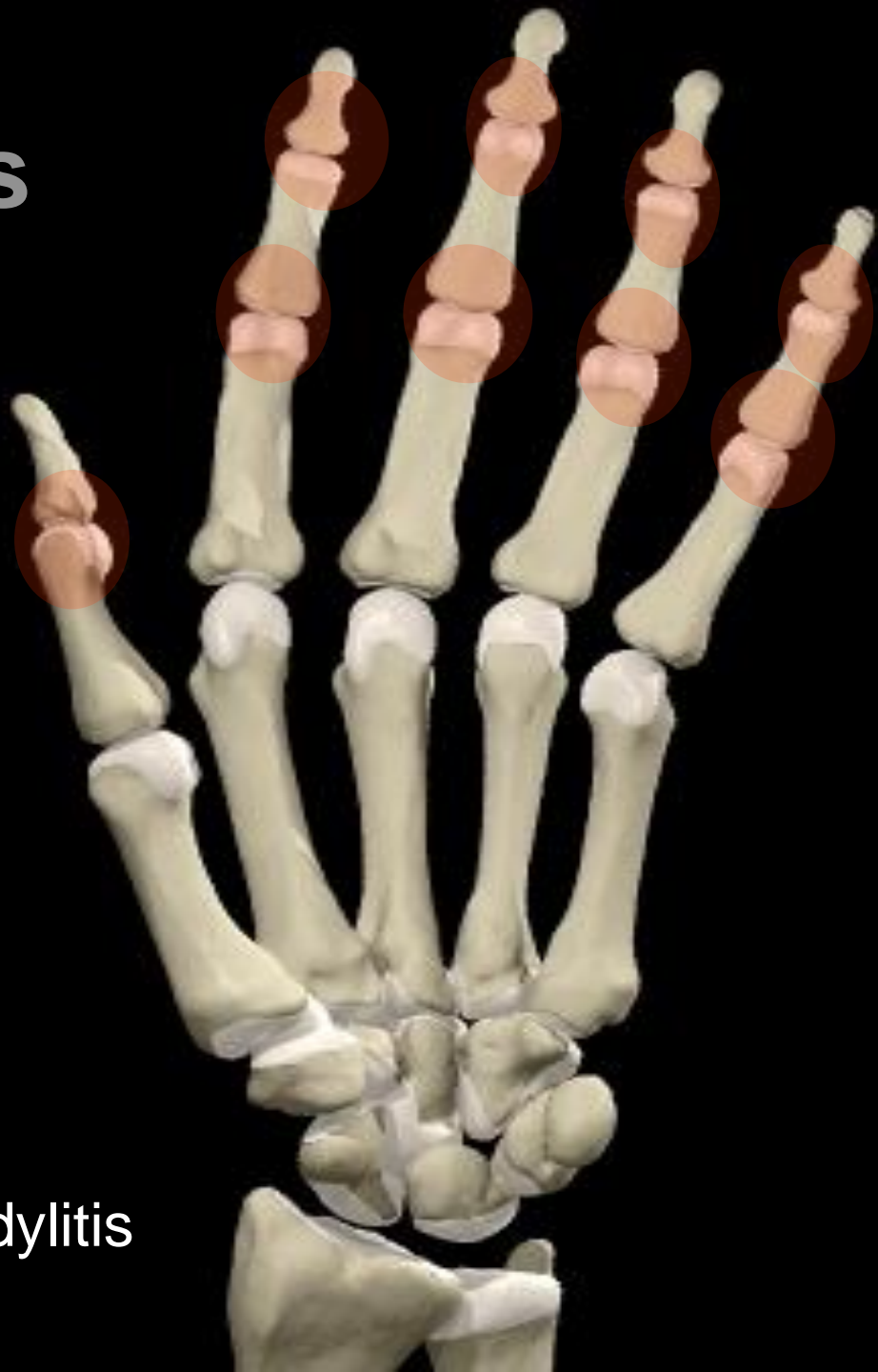Psoriatic arthritis

PIP and DIP > MCP

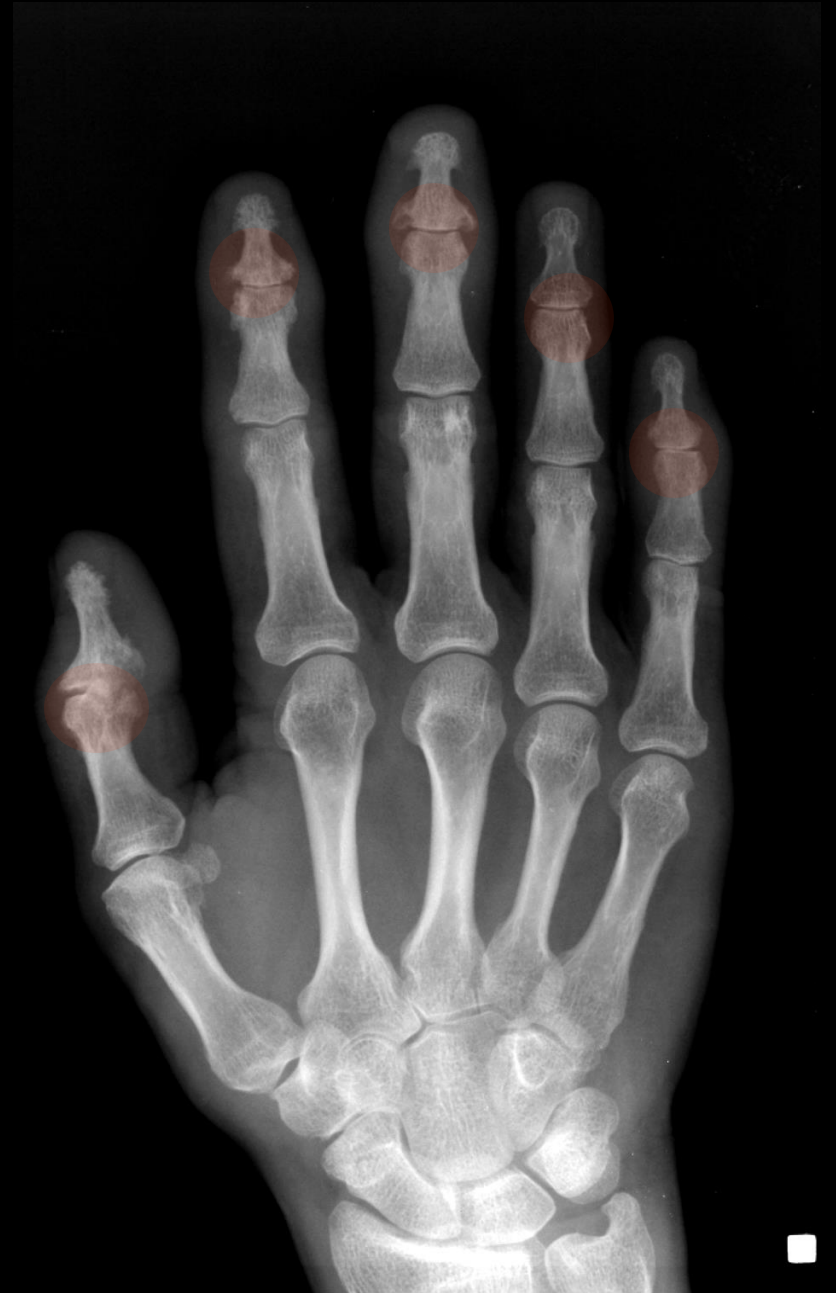New bone formation

Patterns

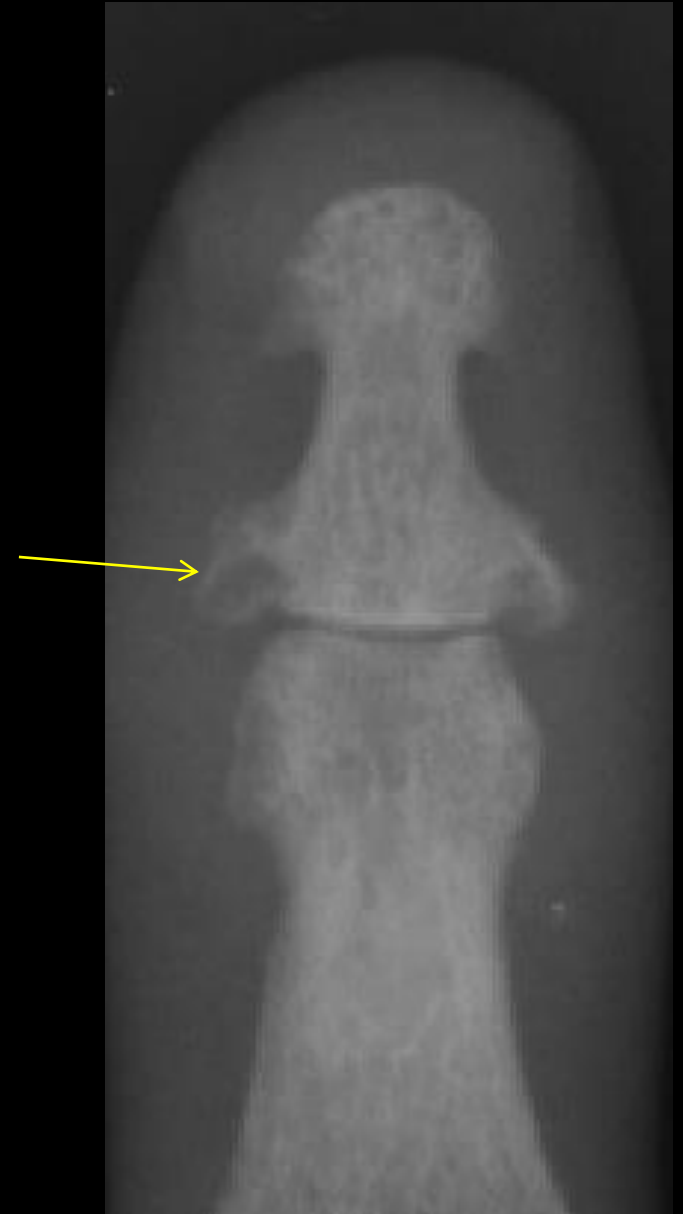- Multiple DIPJs
- Arthritis mutilans
- Resembles RA
- Resembles AS with SIJ/Spondylitis



Psoriatic arthritis

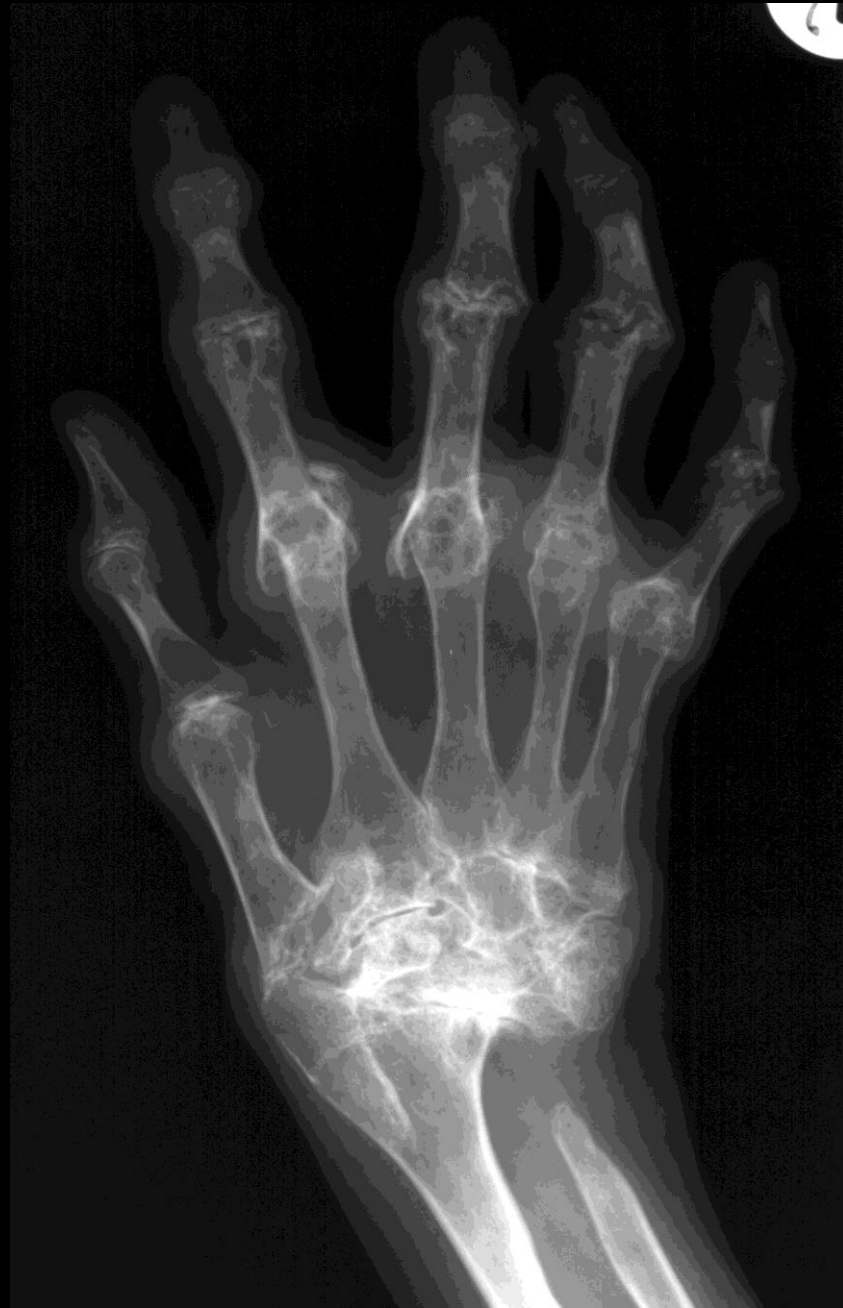

Mouse ear erosion



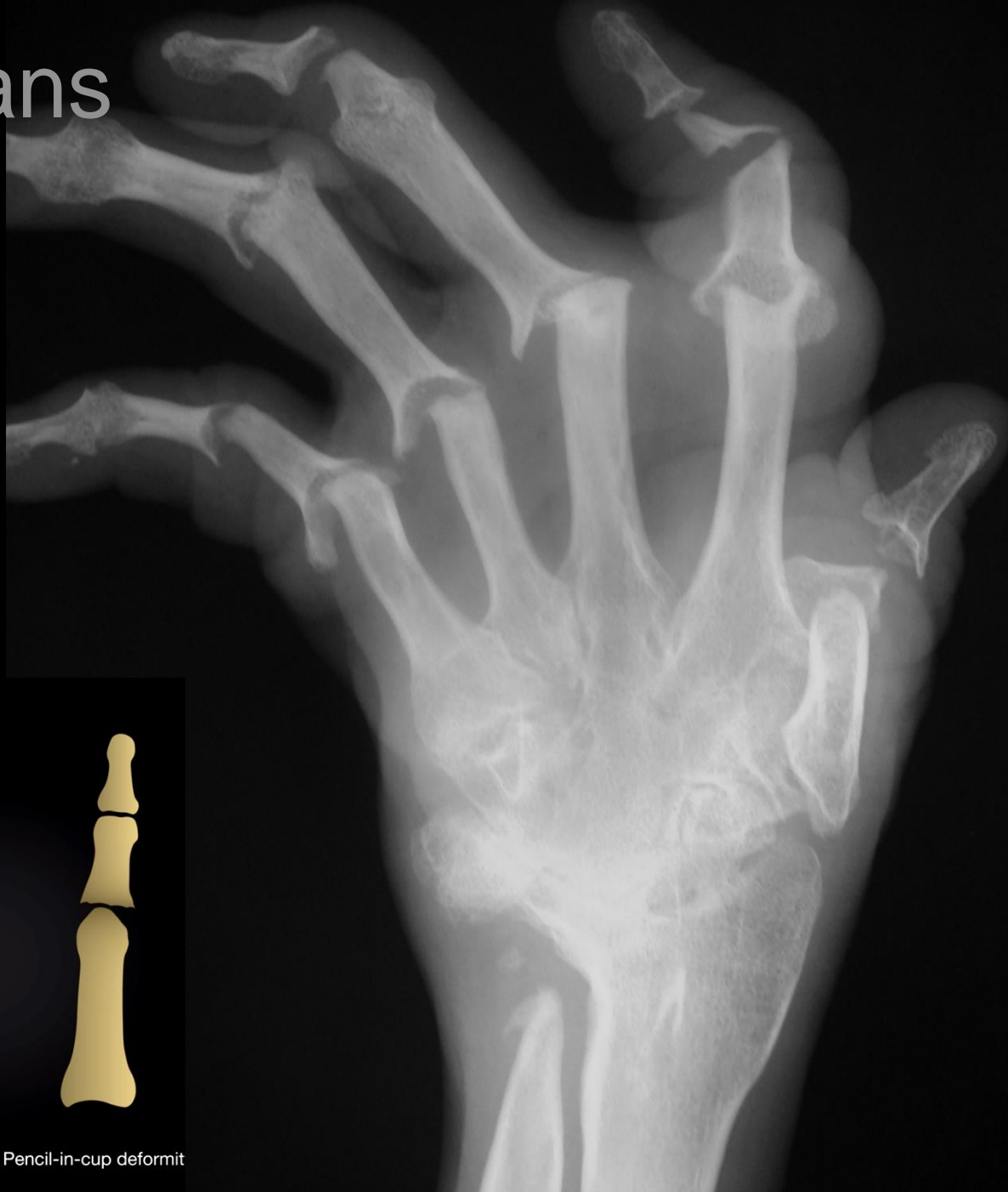Psoriatic arthropathy

Rheumatoid pattern



Arthritis mutilans

Pencil in cup



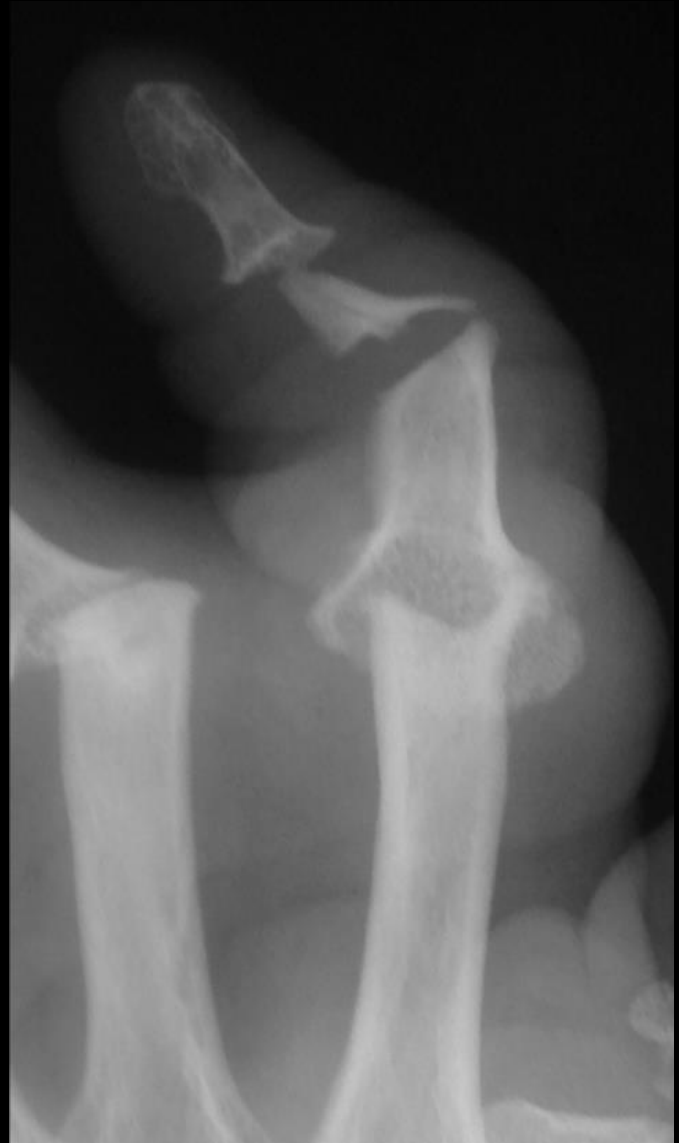Normal



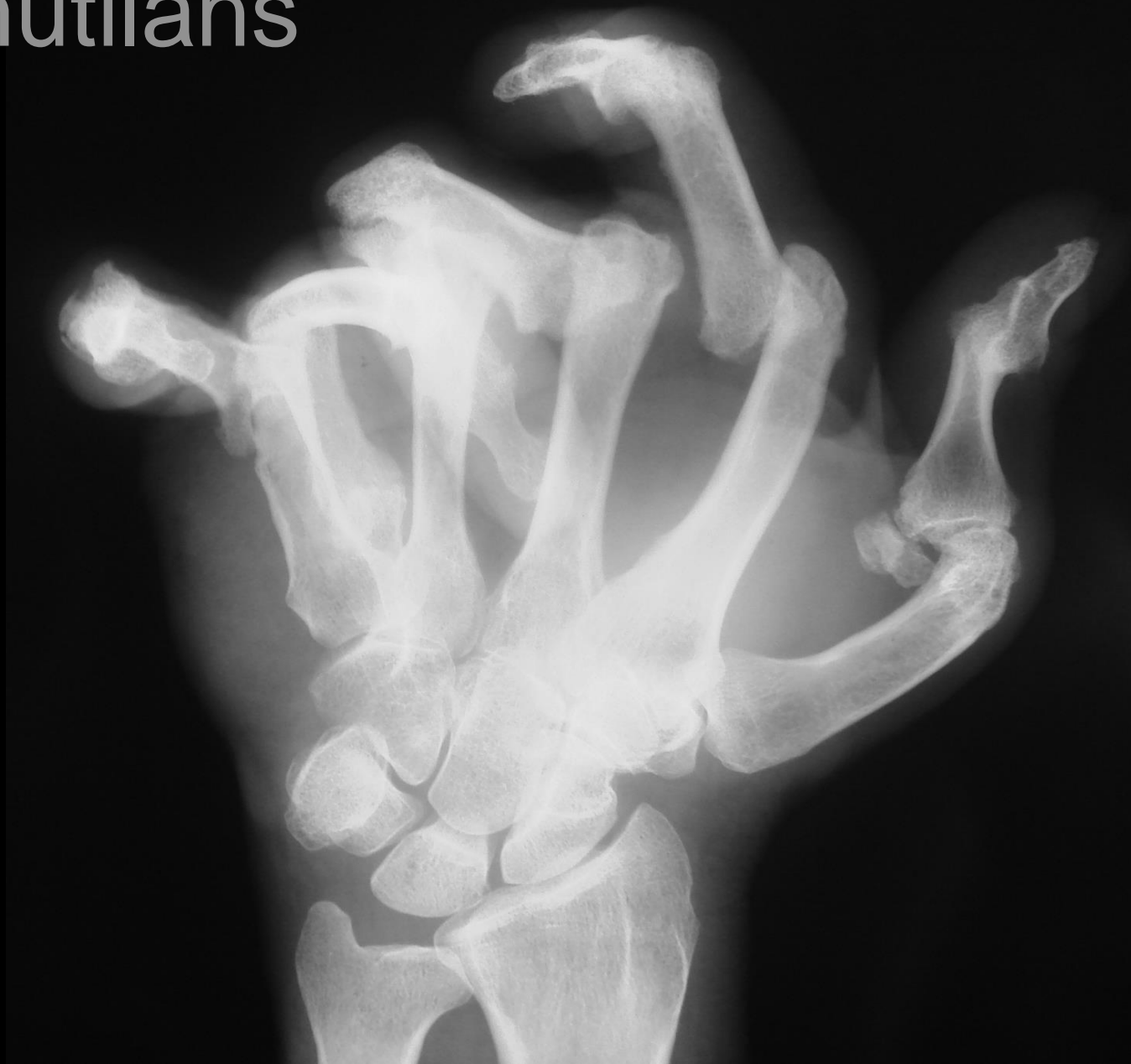Pencil-in-cup deformit

Opera glass hand

Main en lorgnette



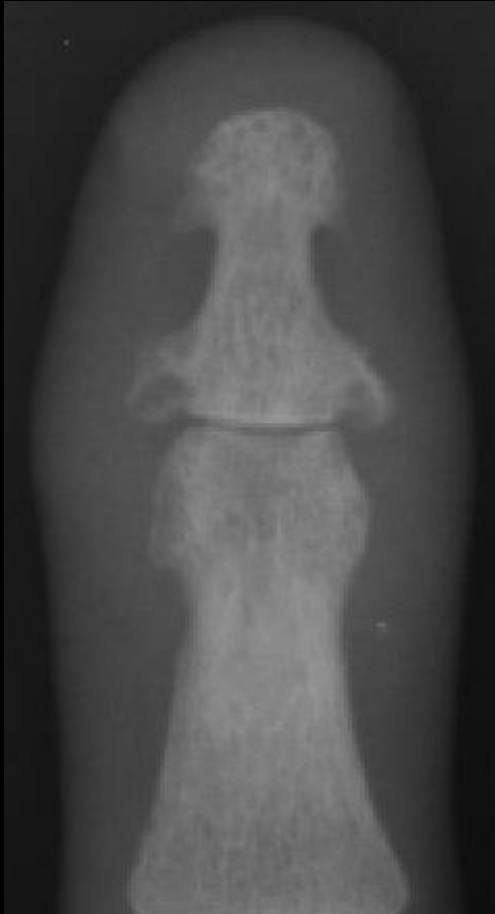Arthritis mutilans



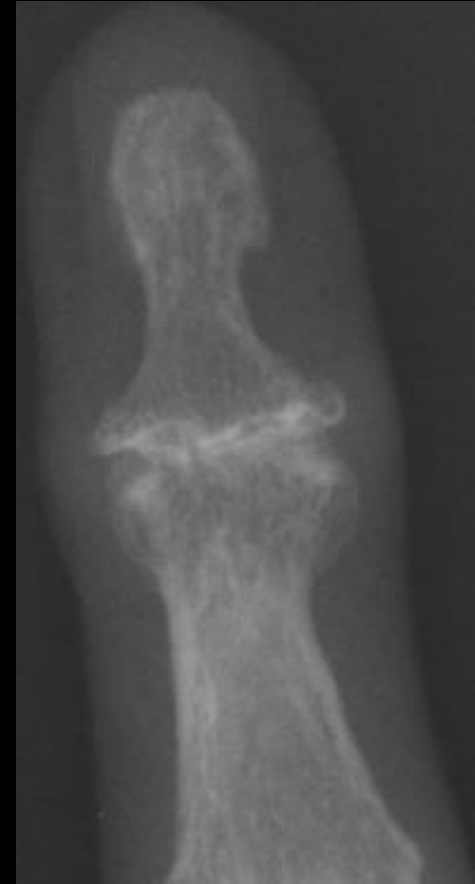Psoriasis

vs.

Erosive OA

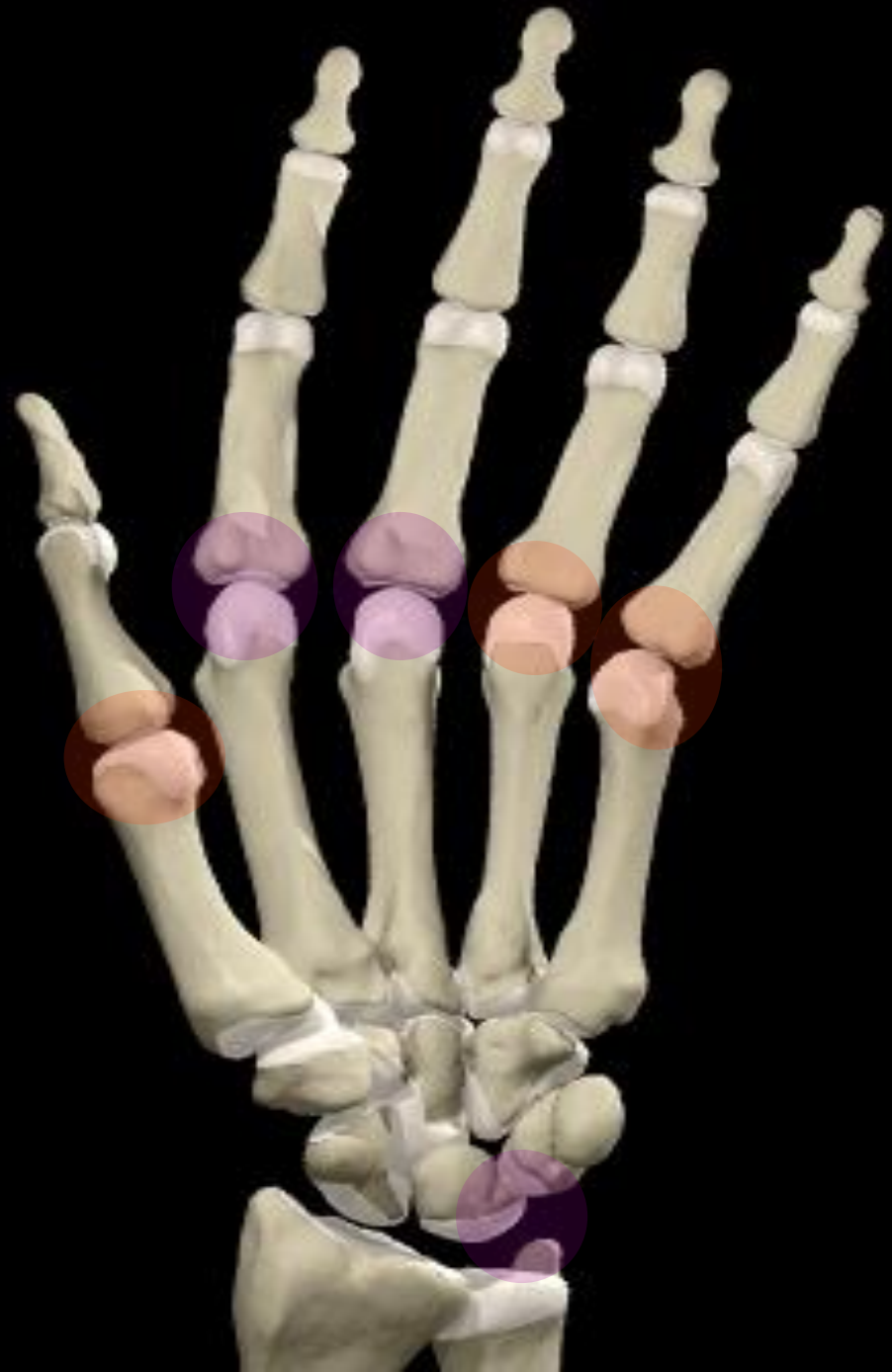

- Whiskering
- New bone
- Mouse ears



- Interdigitation
- Central collapse
- Gull wings

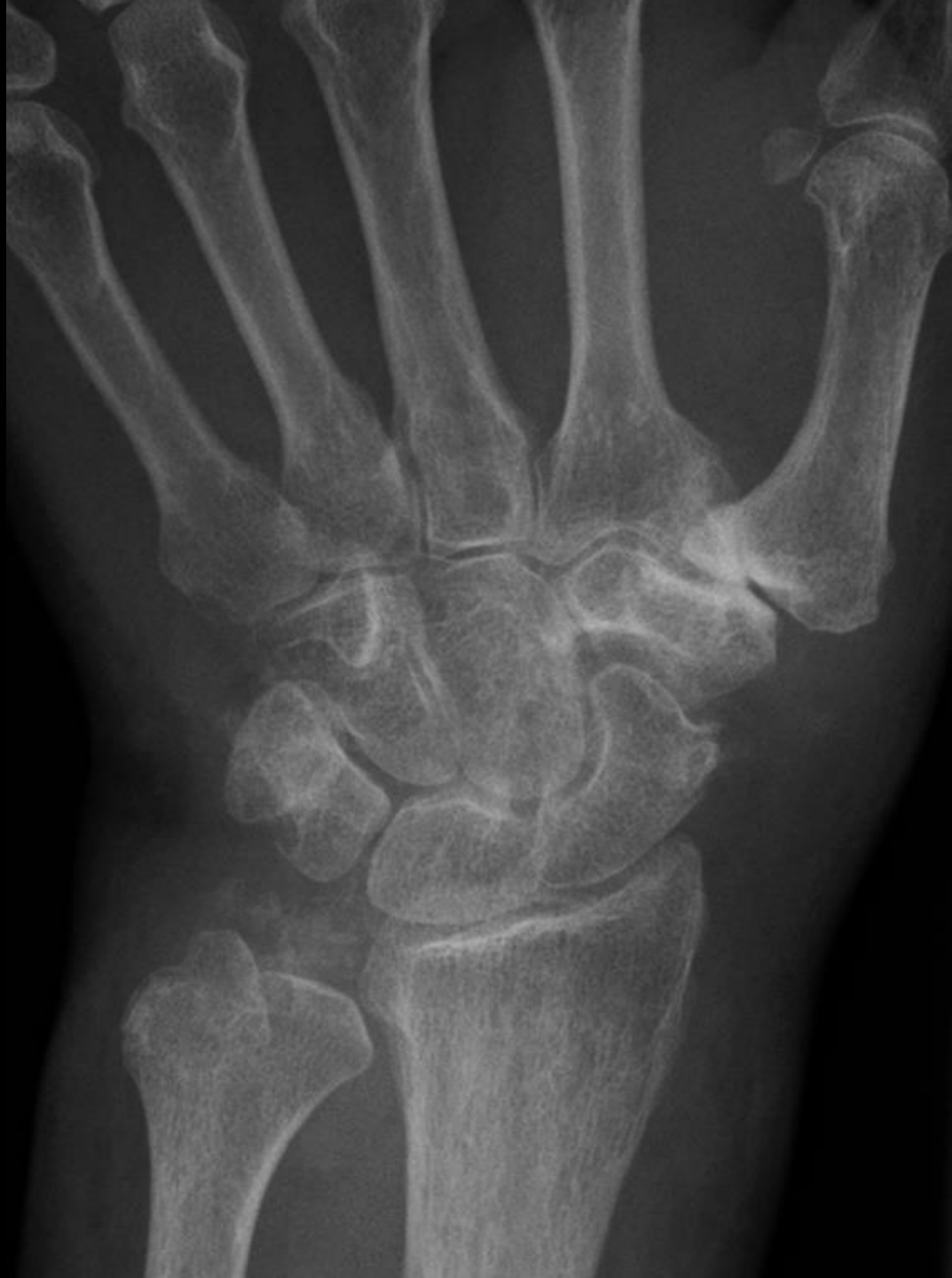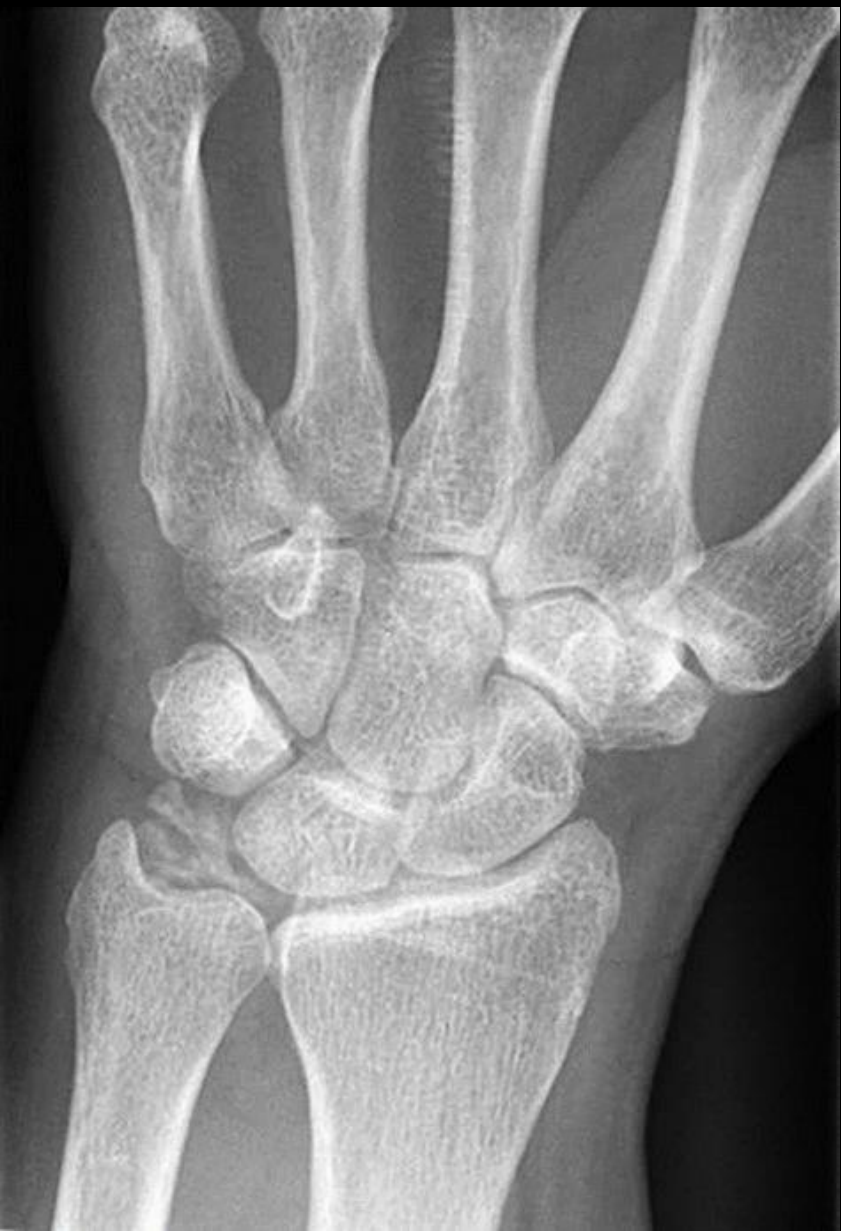CPPD



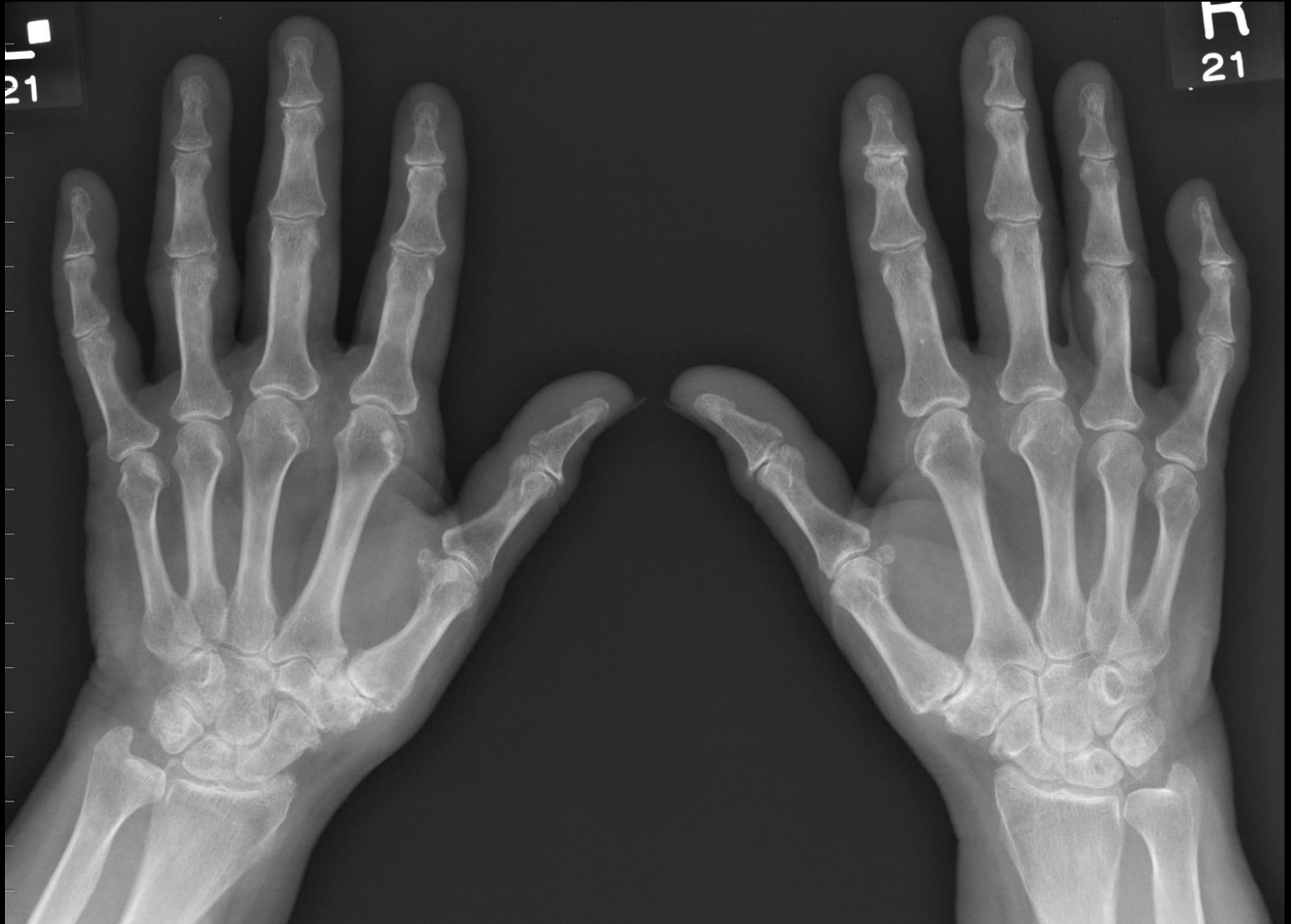CPPD

- Ageing process, usually asymptomatic
- Diagnosis by chondrocalcinosis
- 2nd/3rd MCP
- Associated with hyperparathyroidism, hemochromatosis

CPPD



CPPD



CONCLUSION

- Few diagnoses to consider
- Demographic features
- **Which part of the joint is involved?**
synovium, cartilage or bone?
- **Target approach**

Enthesis diseases

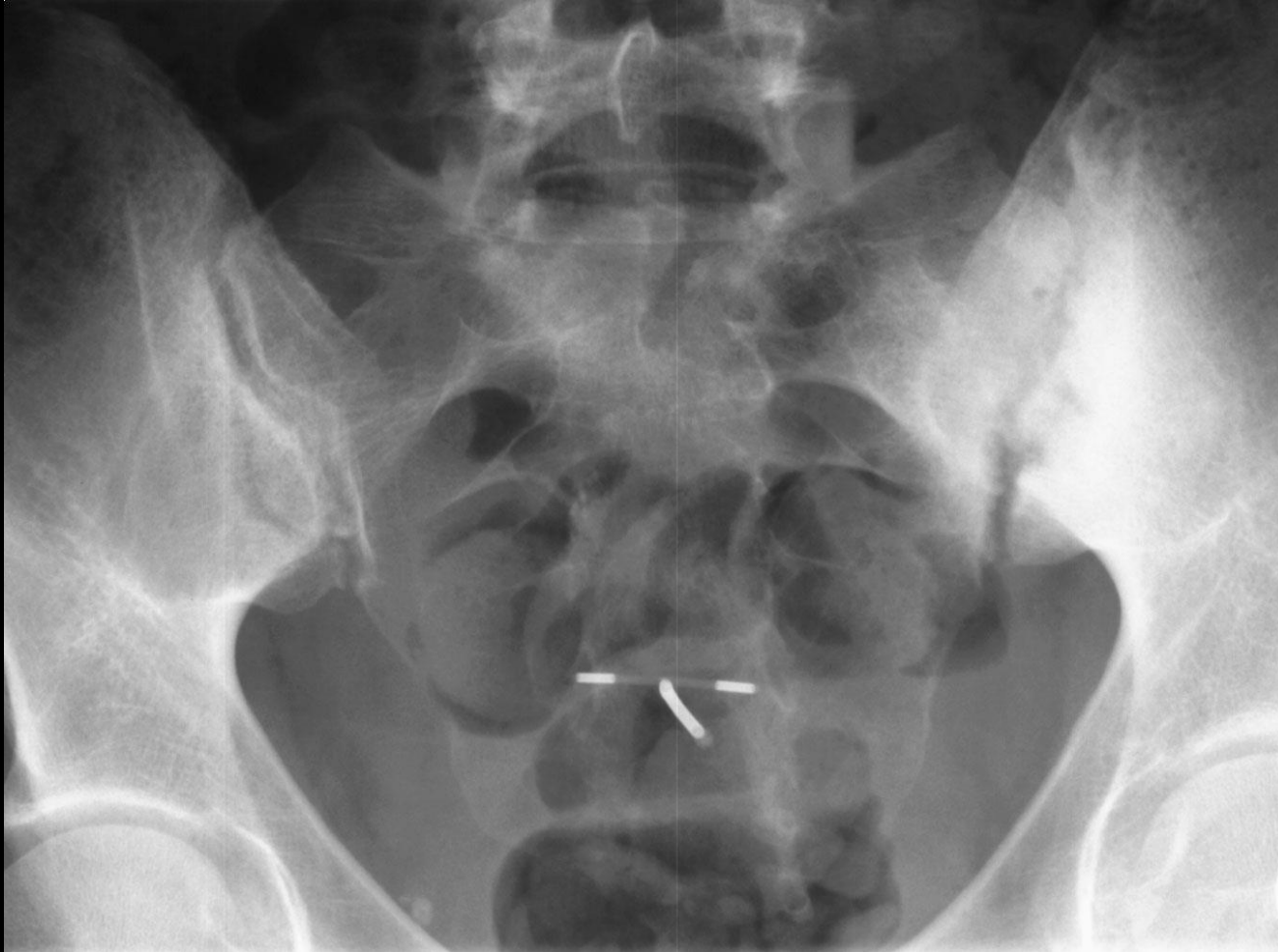Insertion of

Ligaments

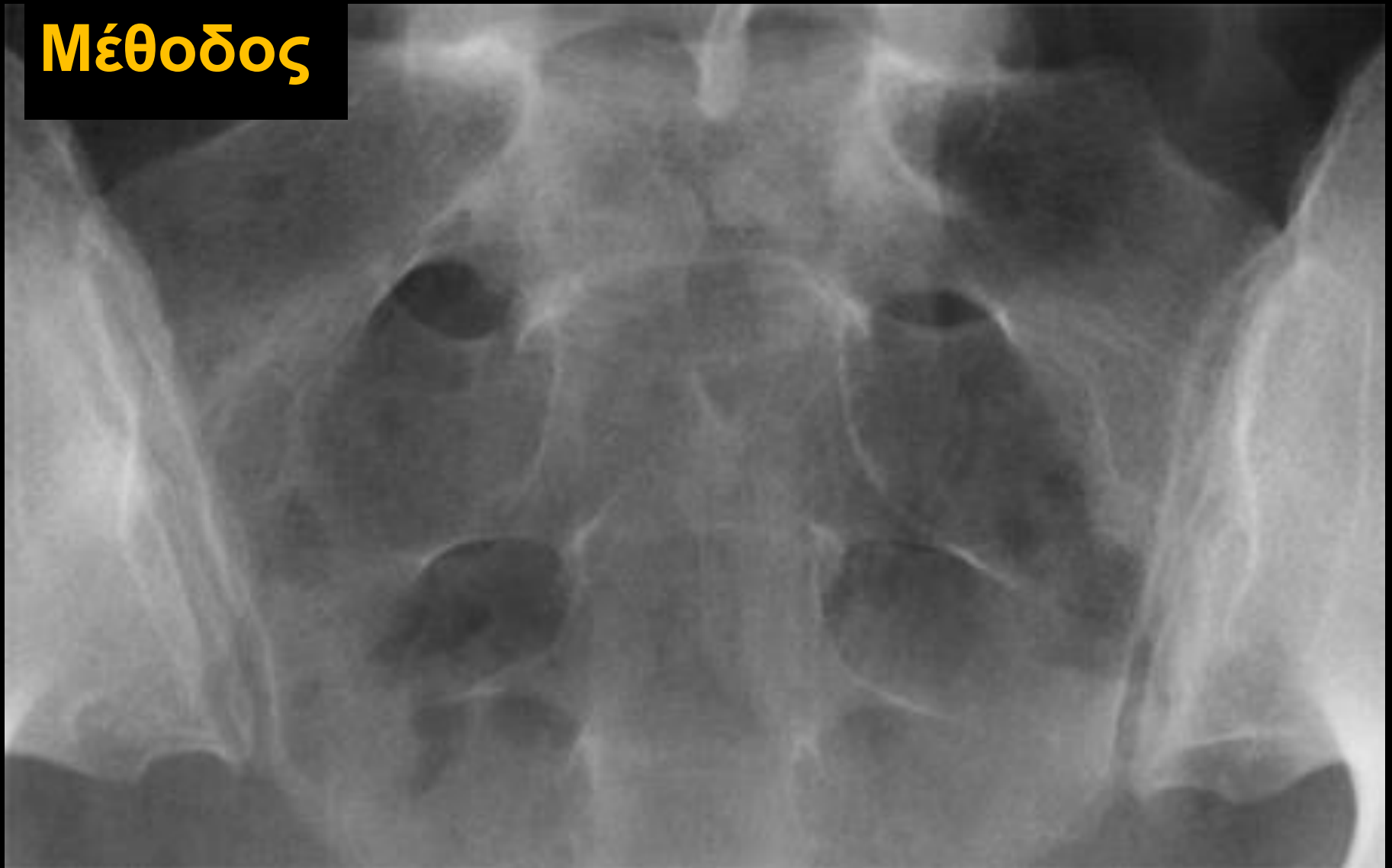
Tendons

Capsule

Sacroiliitis



Μέθοδος



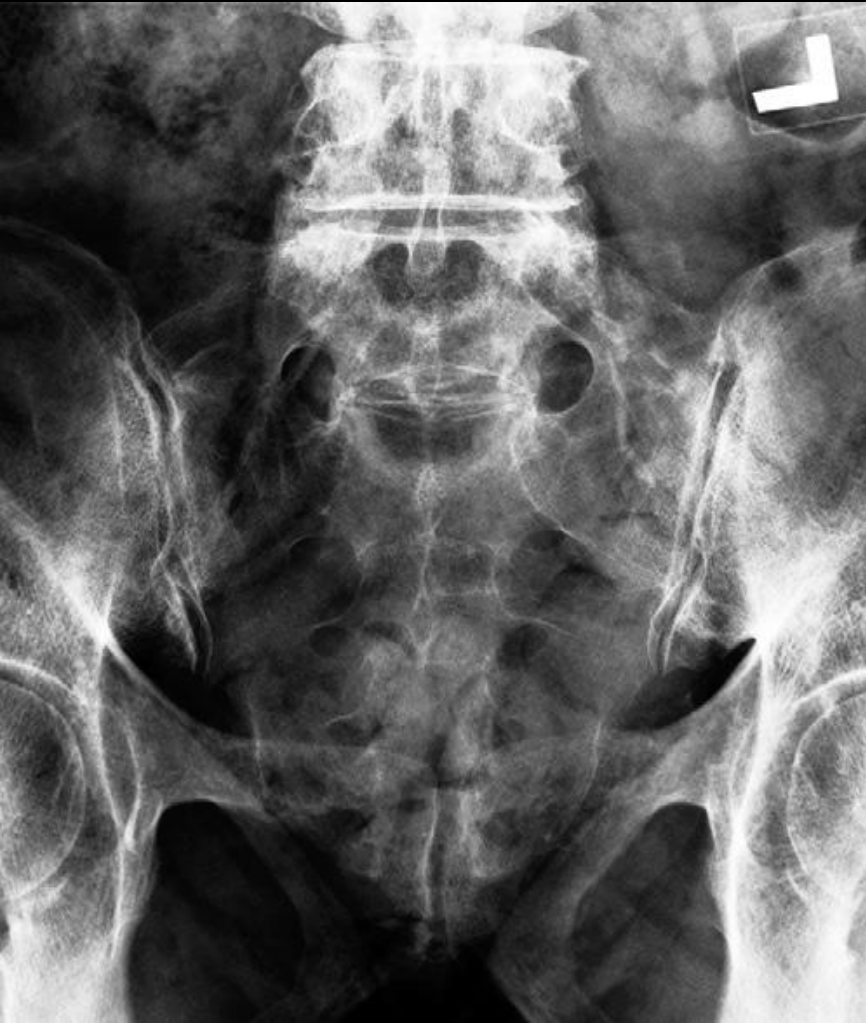Πρώτα ελέγχουμε τη σαφήνεια του υποχόνδριου οστού

Μετά διαβρώσεις (πρώτα λαγόνια μοίρα) – ψευδο-διεύρυνση

Τέλος, σκλήρυνση και αγκύλωση

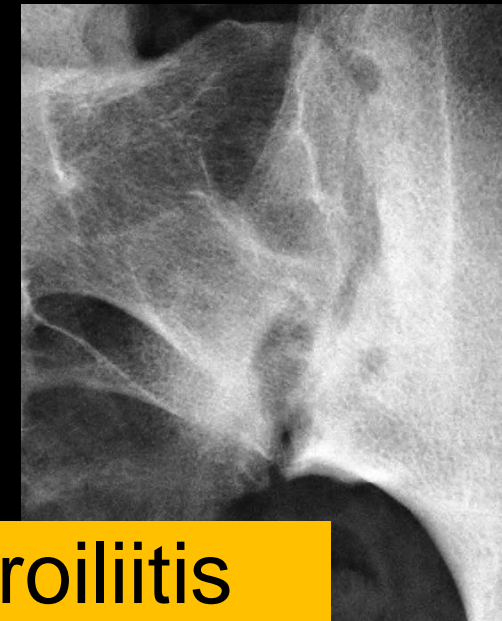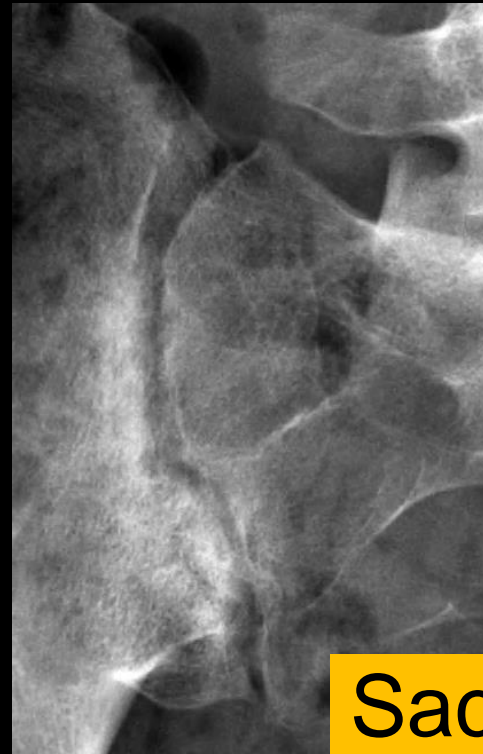Κριτήρια φυσιολογικών SIJ

1. Ομοιόμορφο εύρος αμφοτερόπλευρα
2. Διατήρηση της σκληρυντικής υπαρθρικής γραμμής



Στις SIJ ερευνούμε

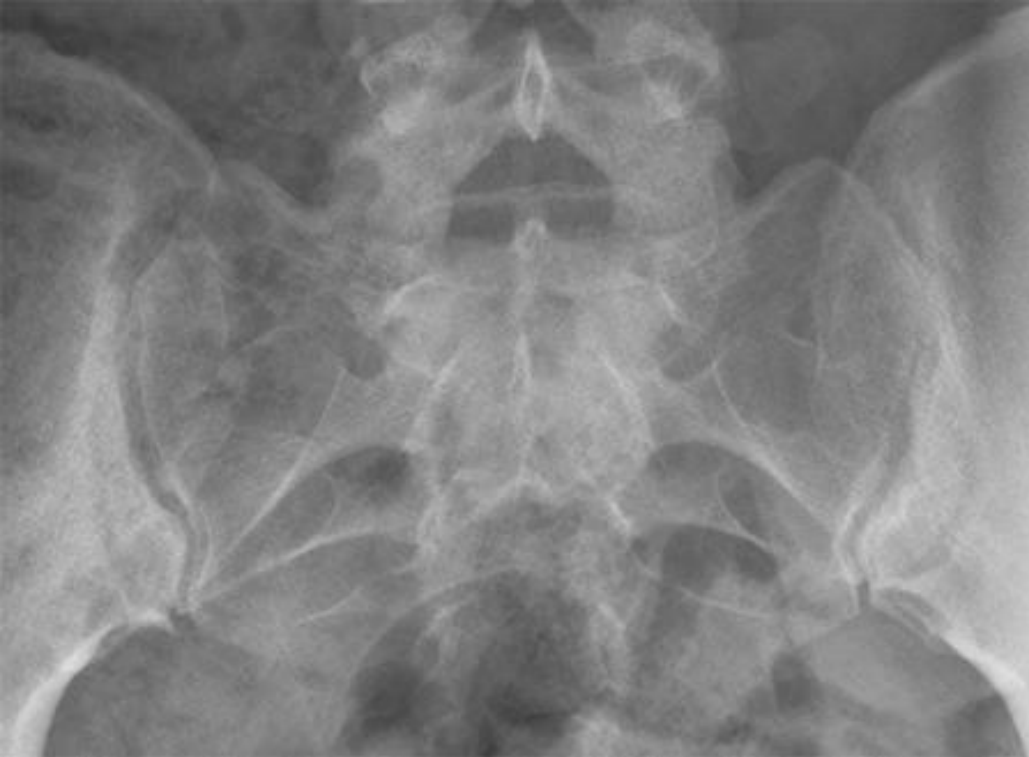1. το εύρος του μεσάρθριου
2. παρουσία και τύπο διαβρώσεων
3. υπαρθρική σκλήρυνση
4. παρουσία και τύπος γεφύρωσης



Sacroiliitis

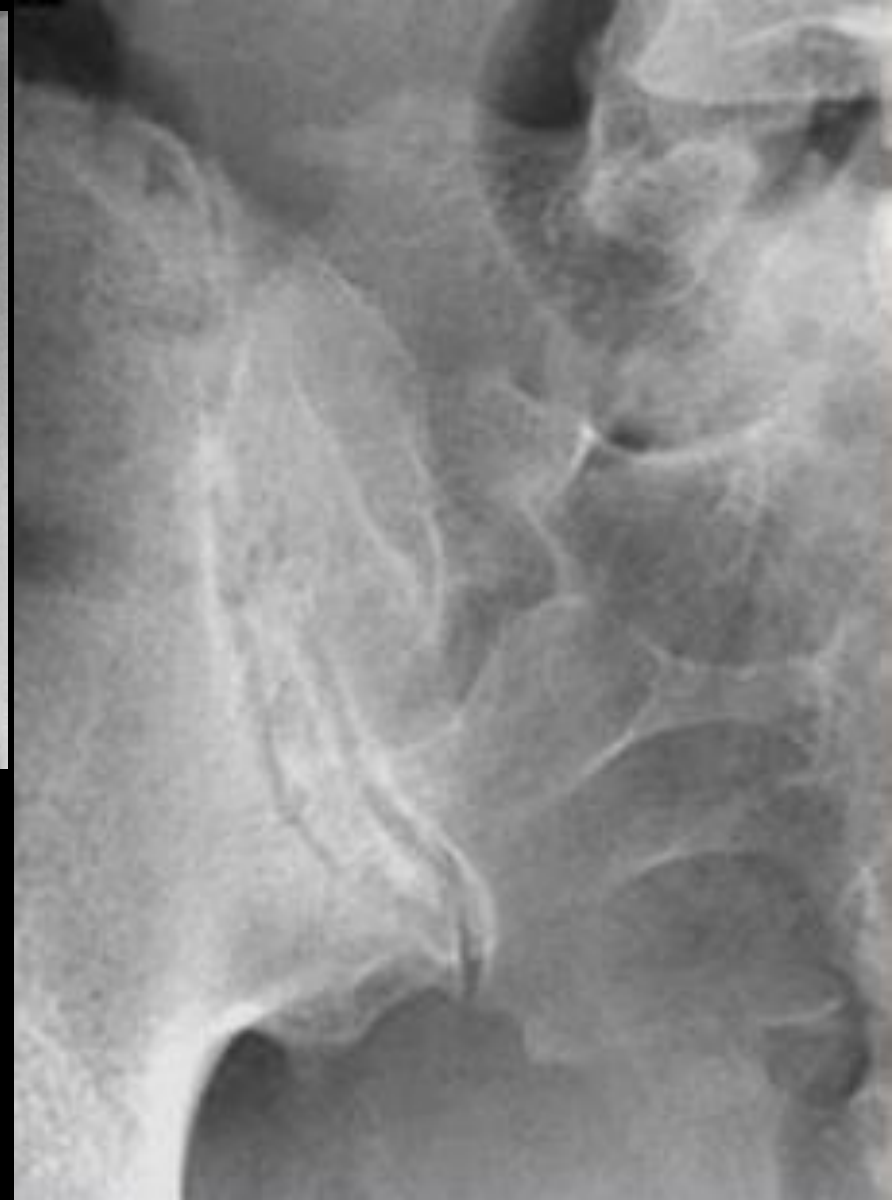
grade I: some blurring of joint margins - suspicious
grade II: minimal sclerosis with some erosion

Grading



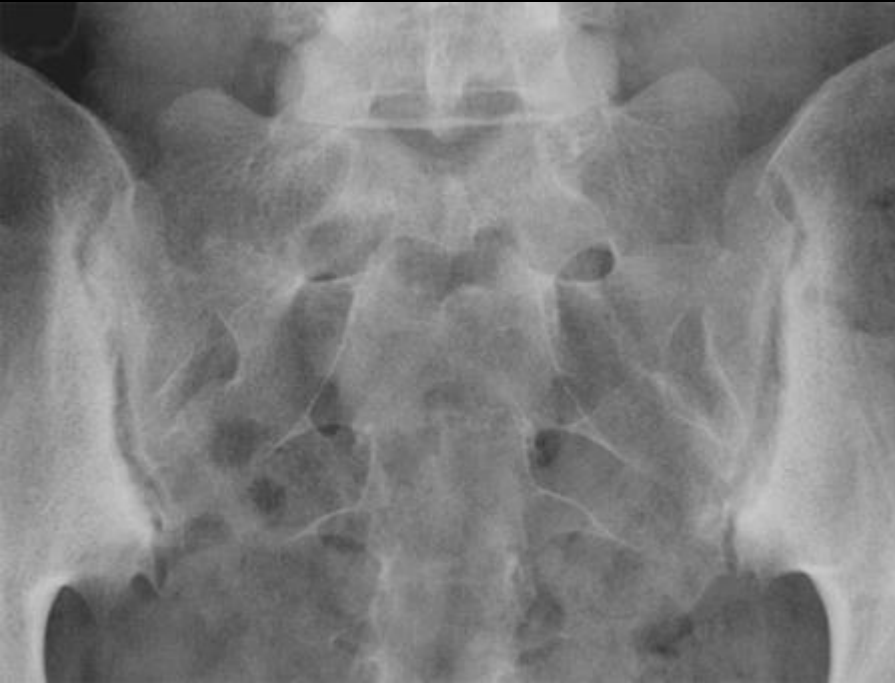I

II

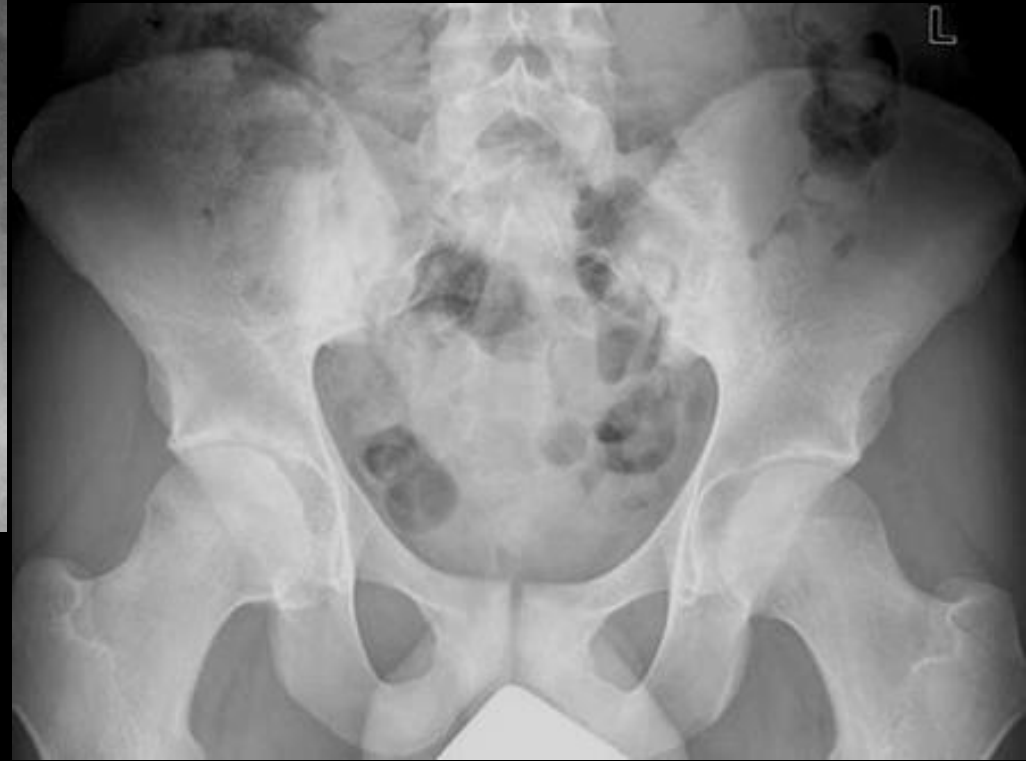

Grading

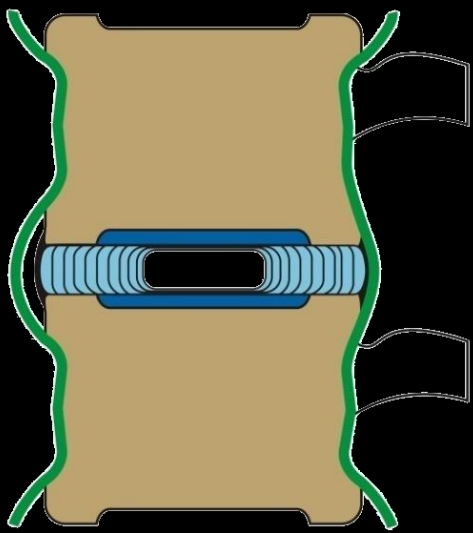
grade III: definite sclerosis on both sides of joint
severe erosions with widening of joint space with
or without ankylosis
grade IV: complete ankylosis



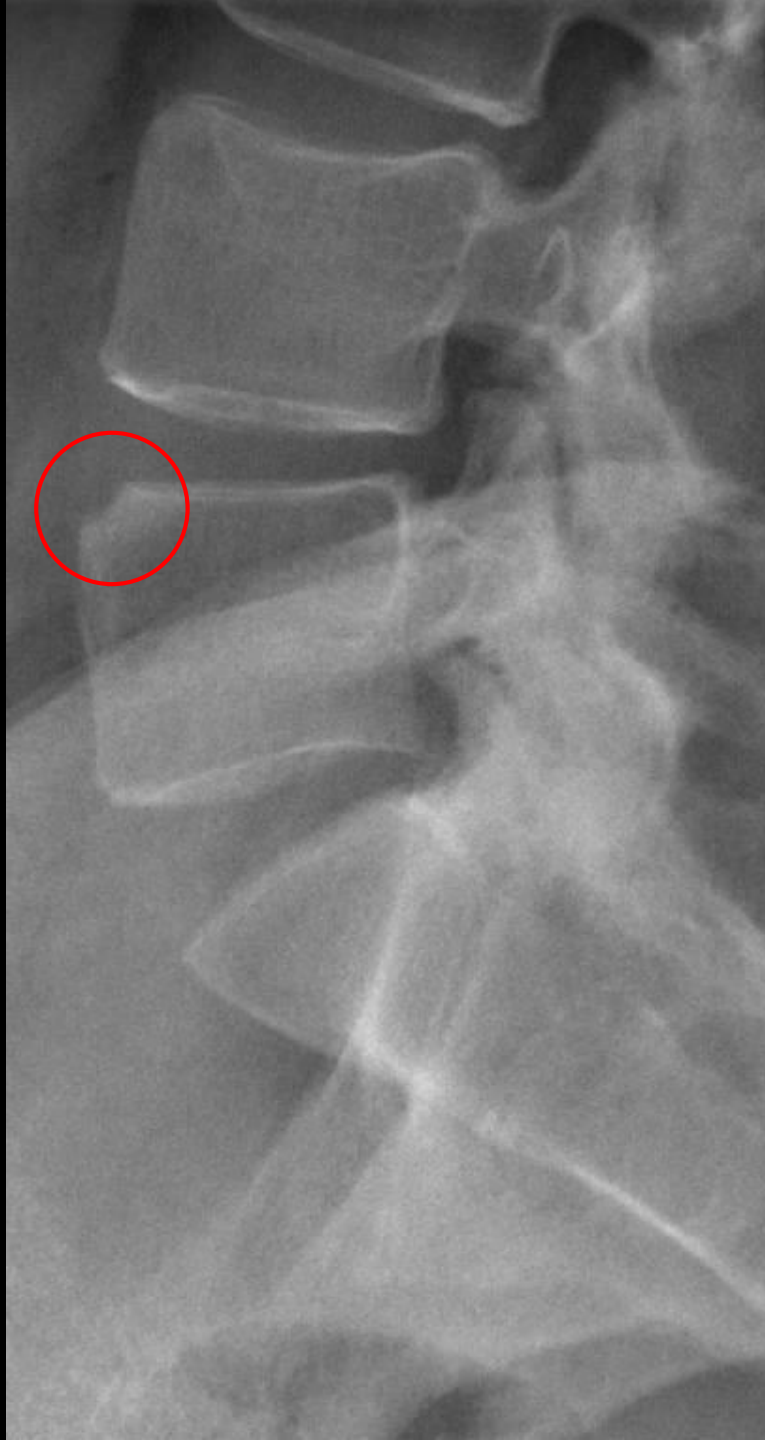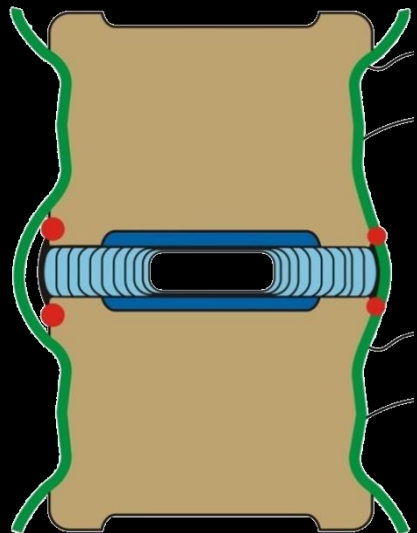
III



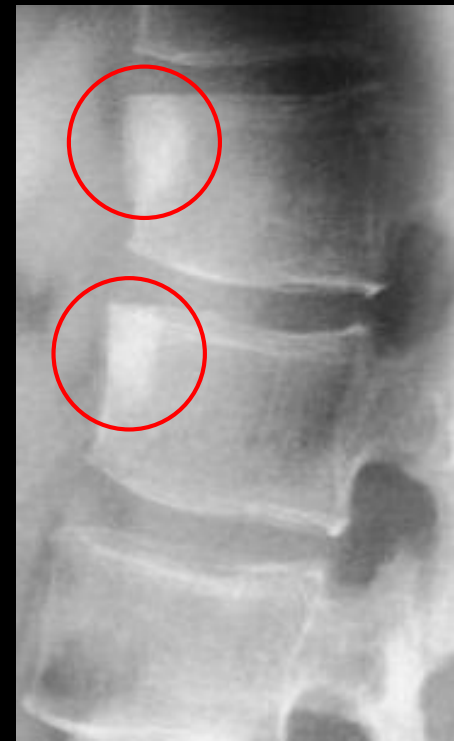
IV

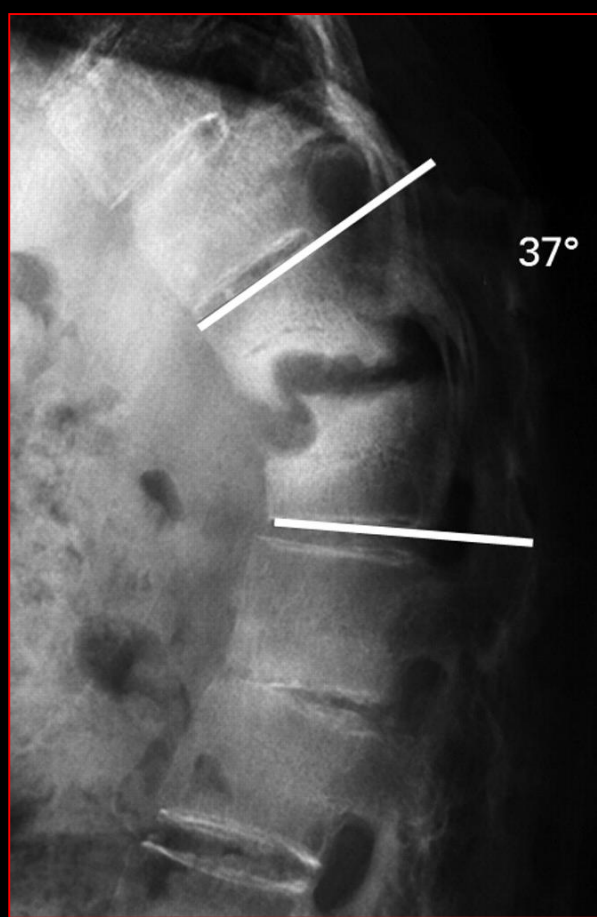


Ένθεση στη ΣΣ:



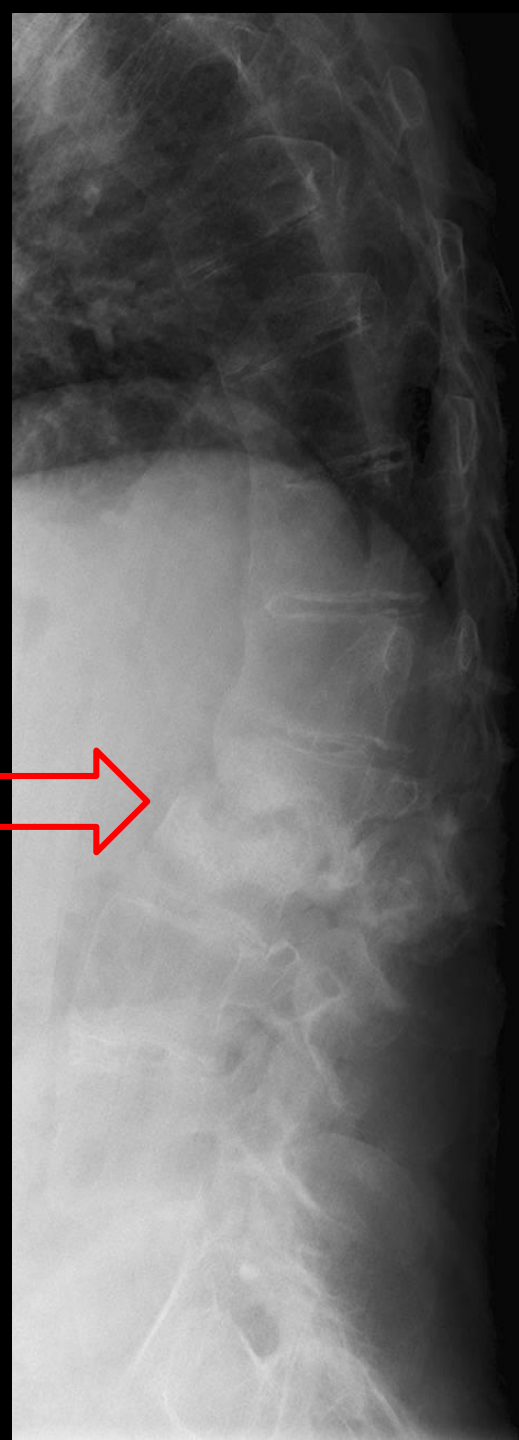
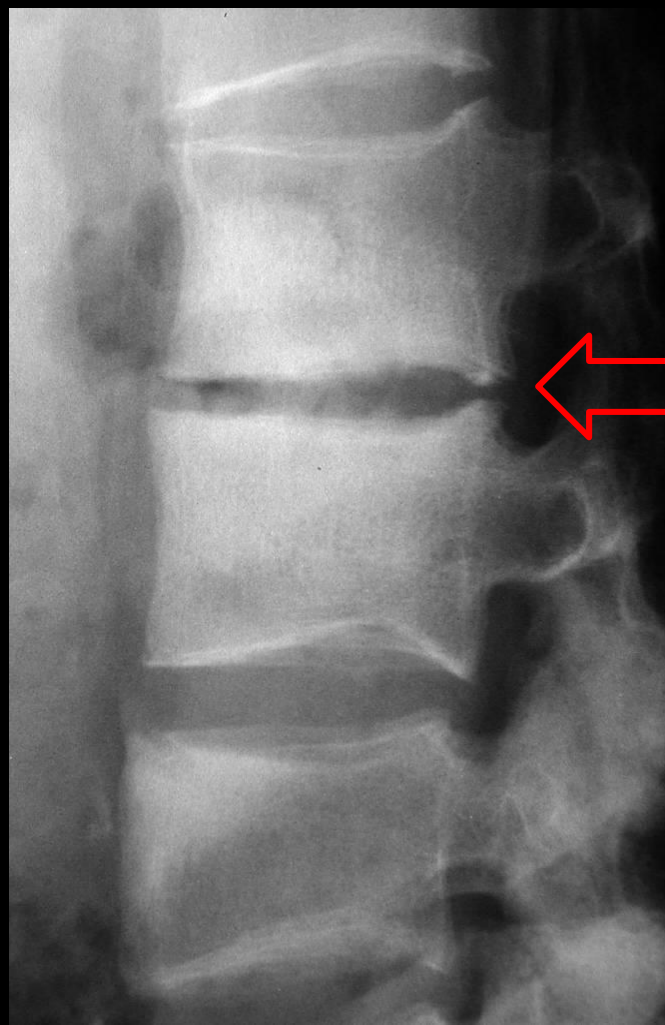
Romanus lesion
"shiny" corners=osteitis





Ένθεση στη ΣΣ:


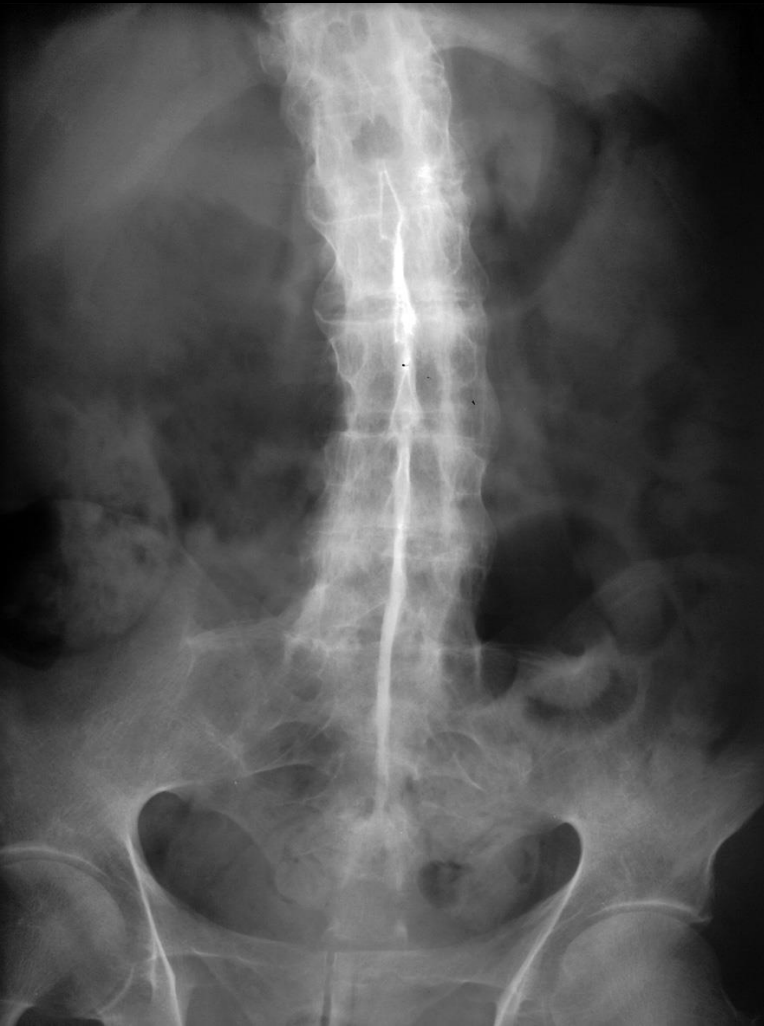
37°



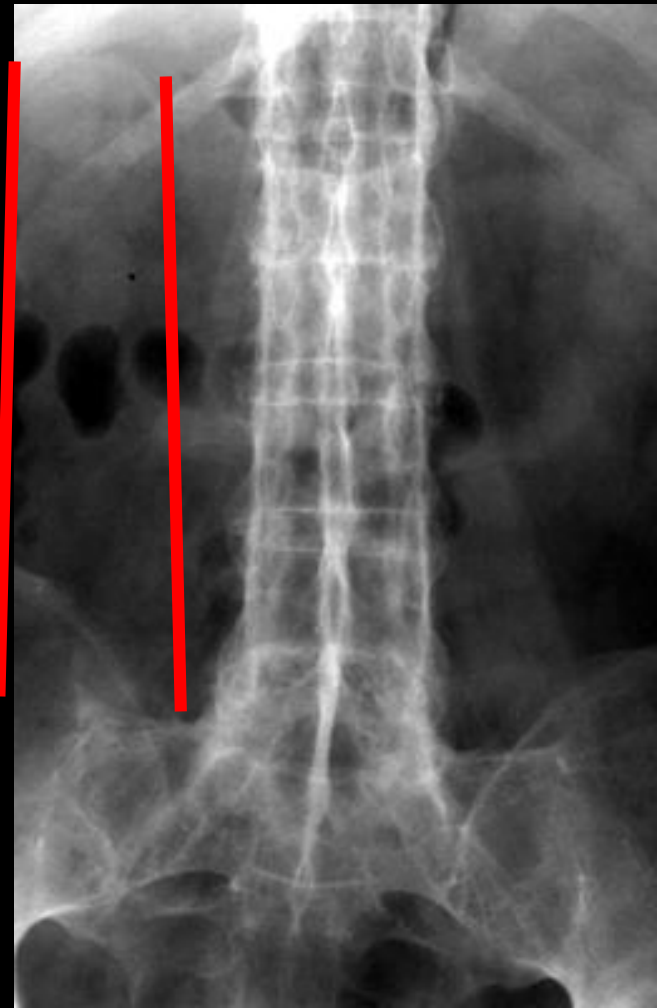
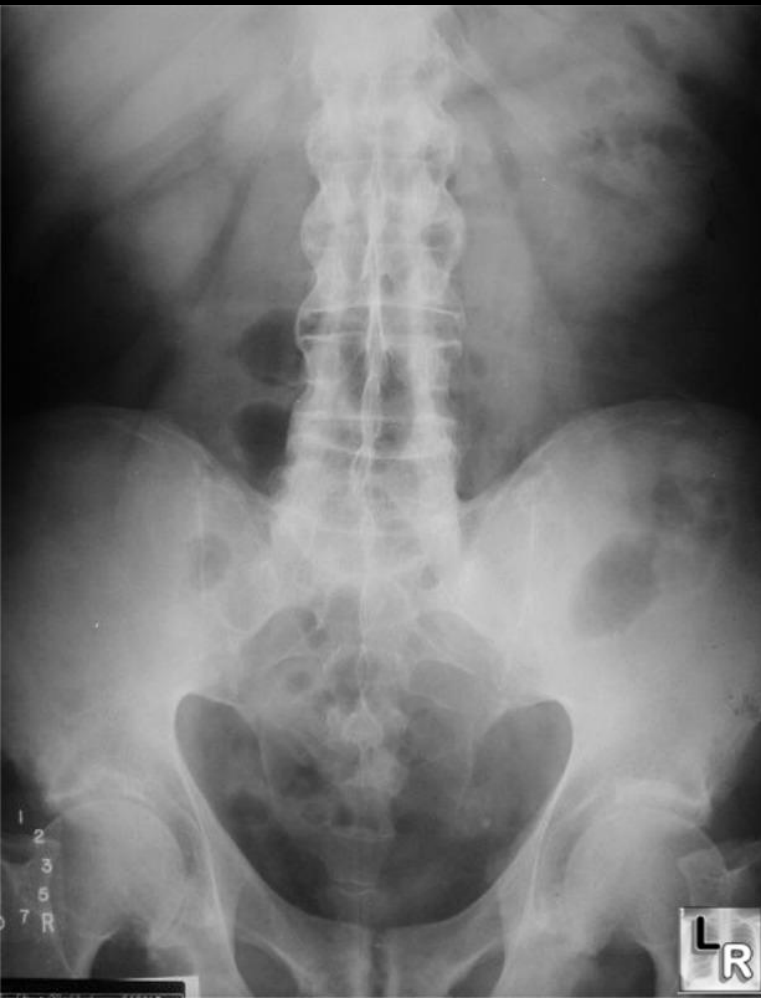Άσηπτη σπονδυλοδίσκίτιδα

Andersson's lesion

“Dagger sign”: ossification of posterior interspinous ligaments

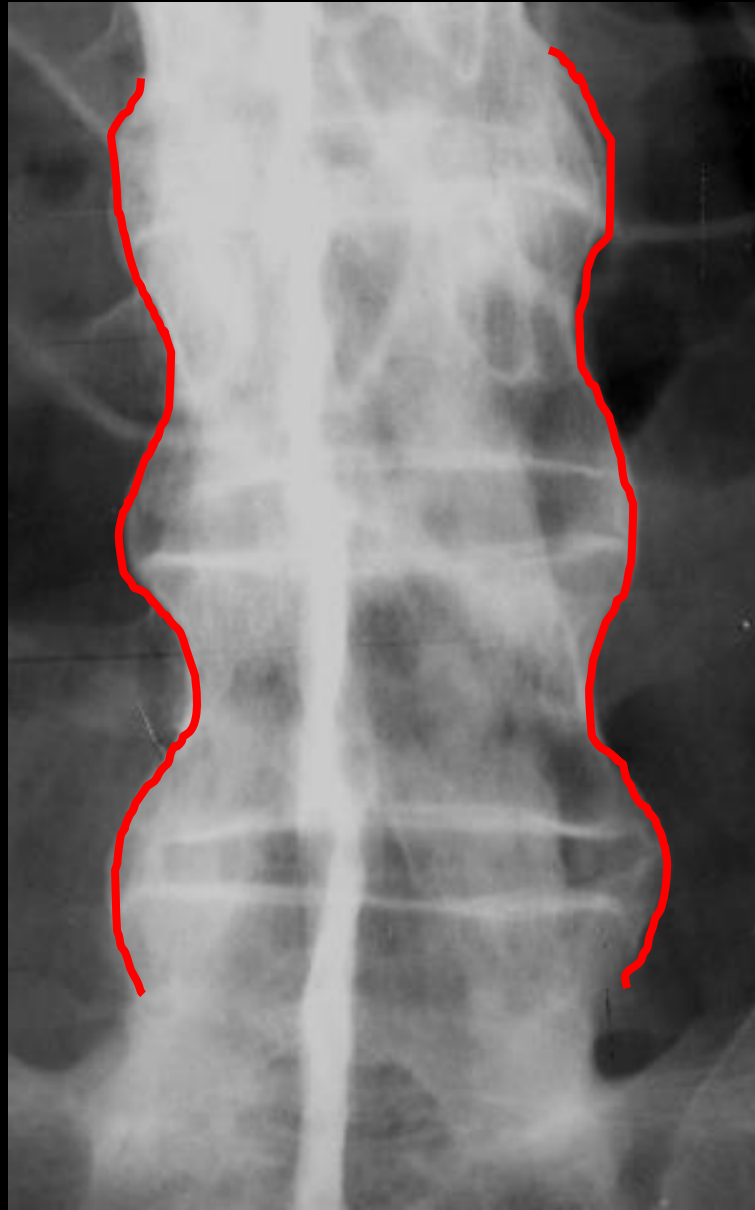
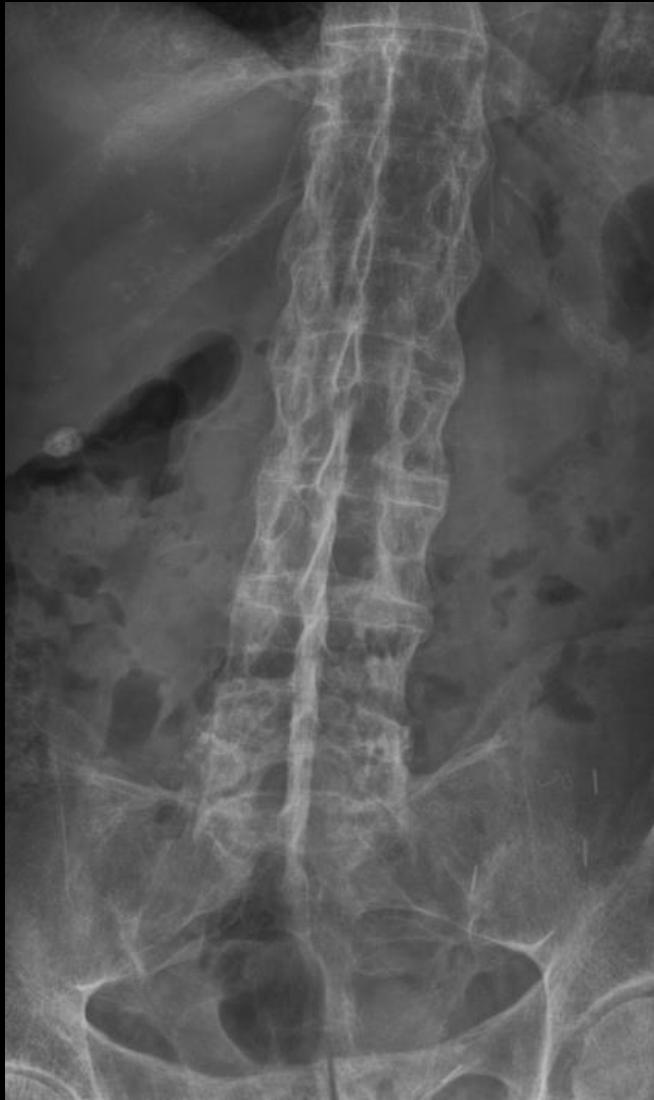

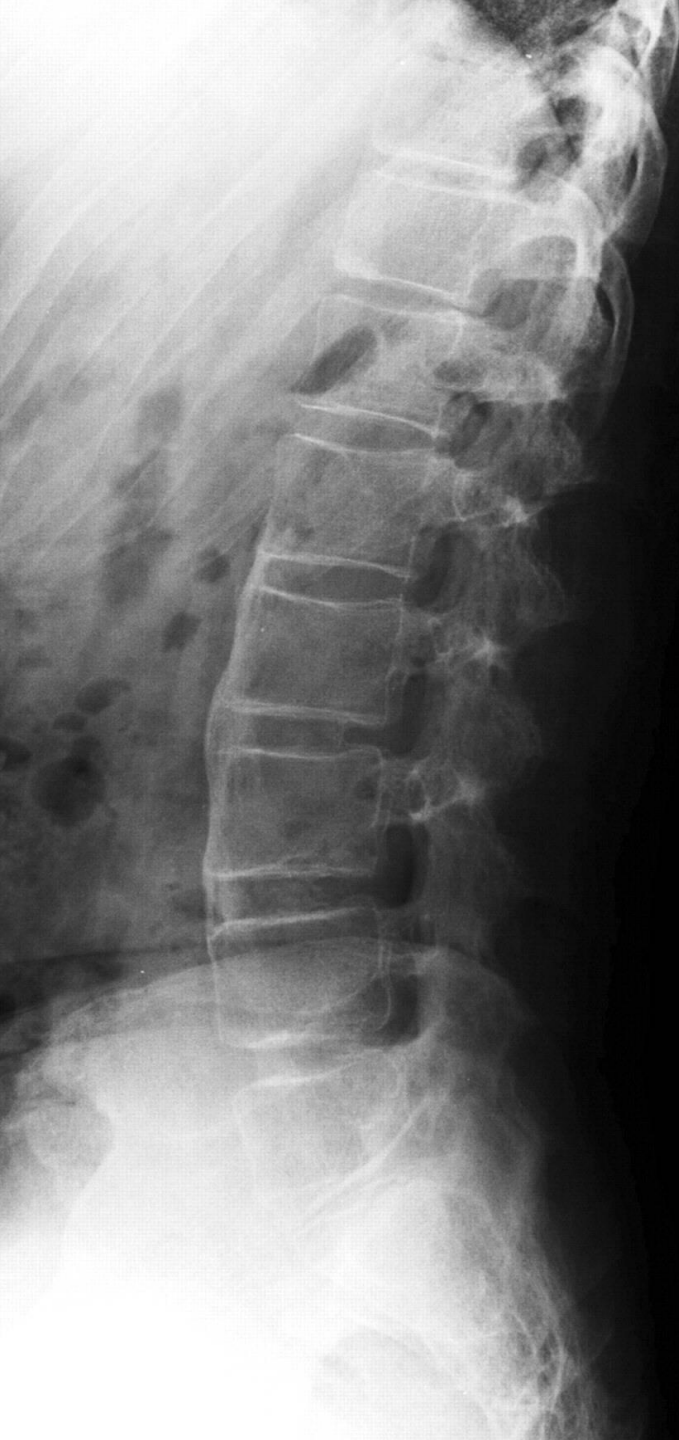
“Trolley track” sign: ossification of facet joints



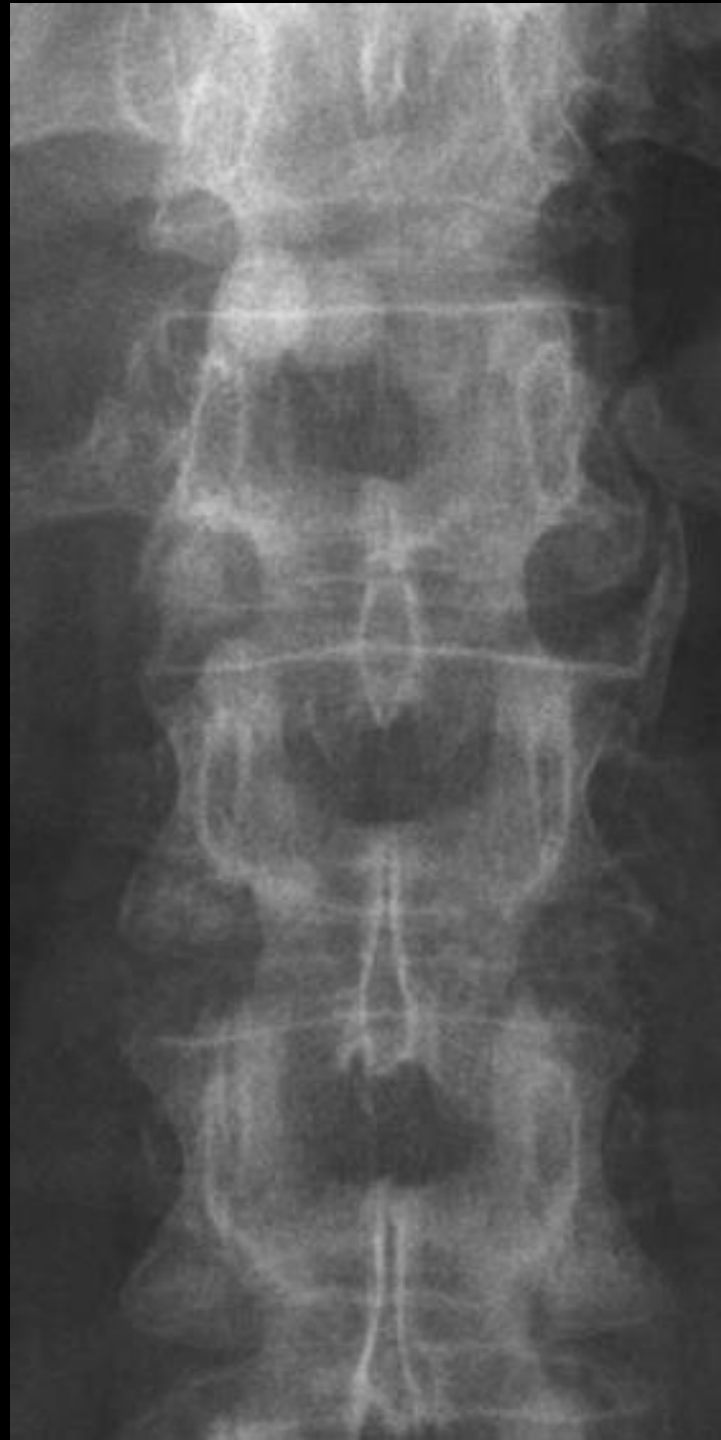Bamboo spine

“Ghost” SIJ



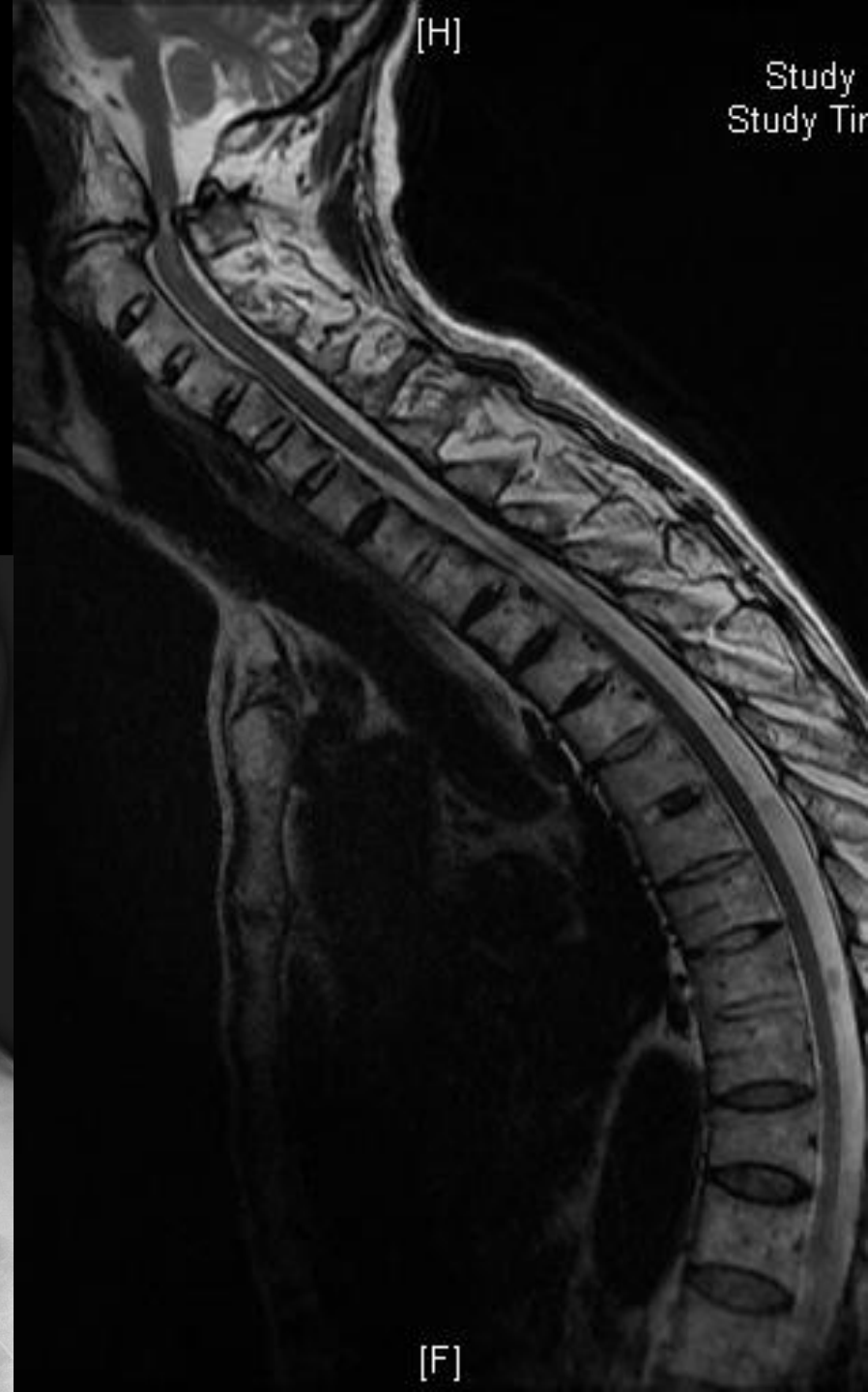
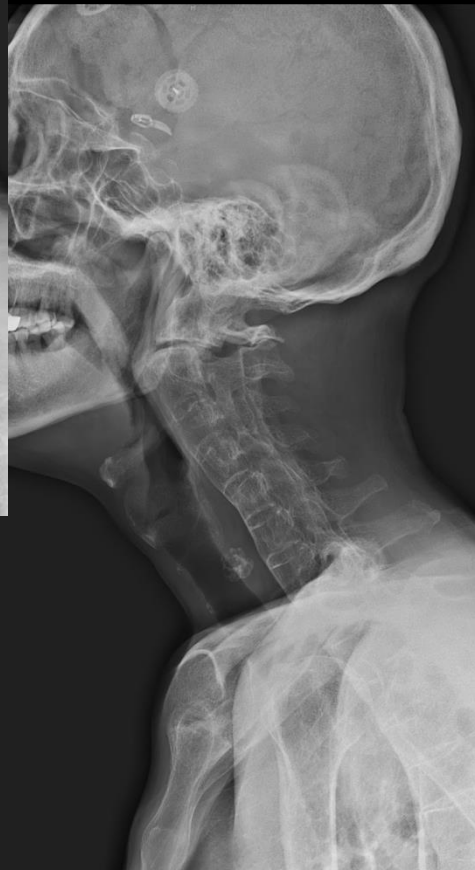
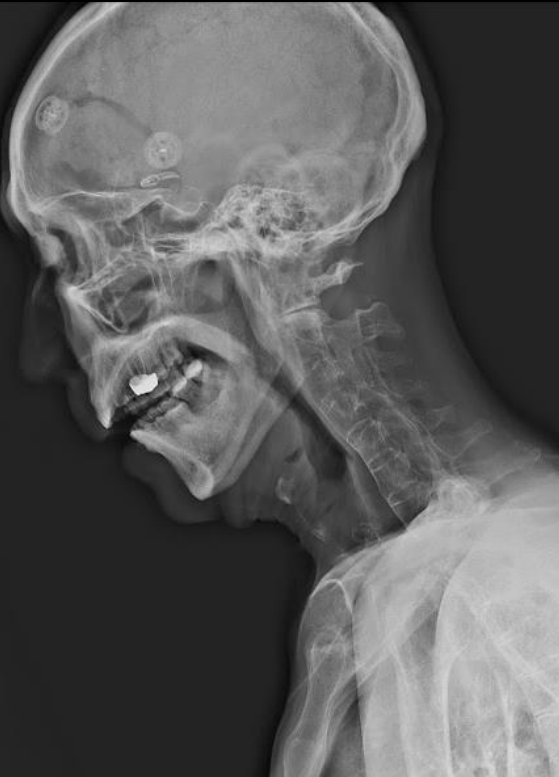
AS PsA



Αστάθεια A1-A2

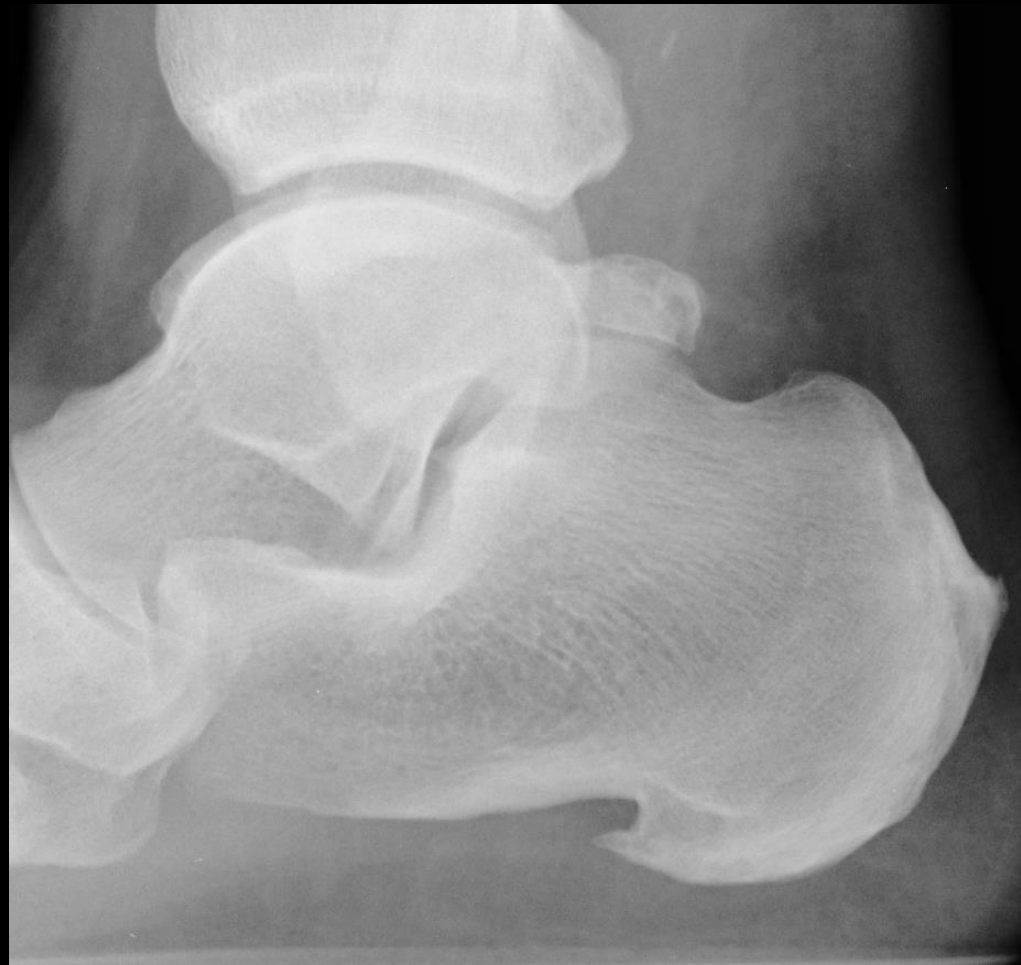65^α, προοδευτική παραπάρεση
από 2 ετών



Is the enthesopathy erosive?

Look at

- Achilles insertion
- Plantar fascia insertion



Reiter's disease

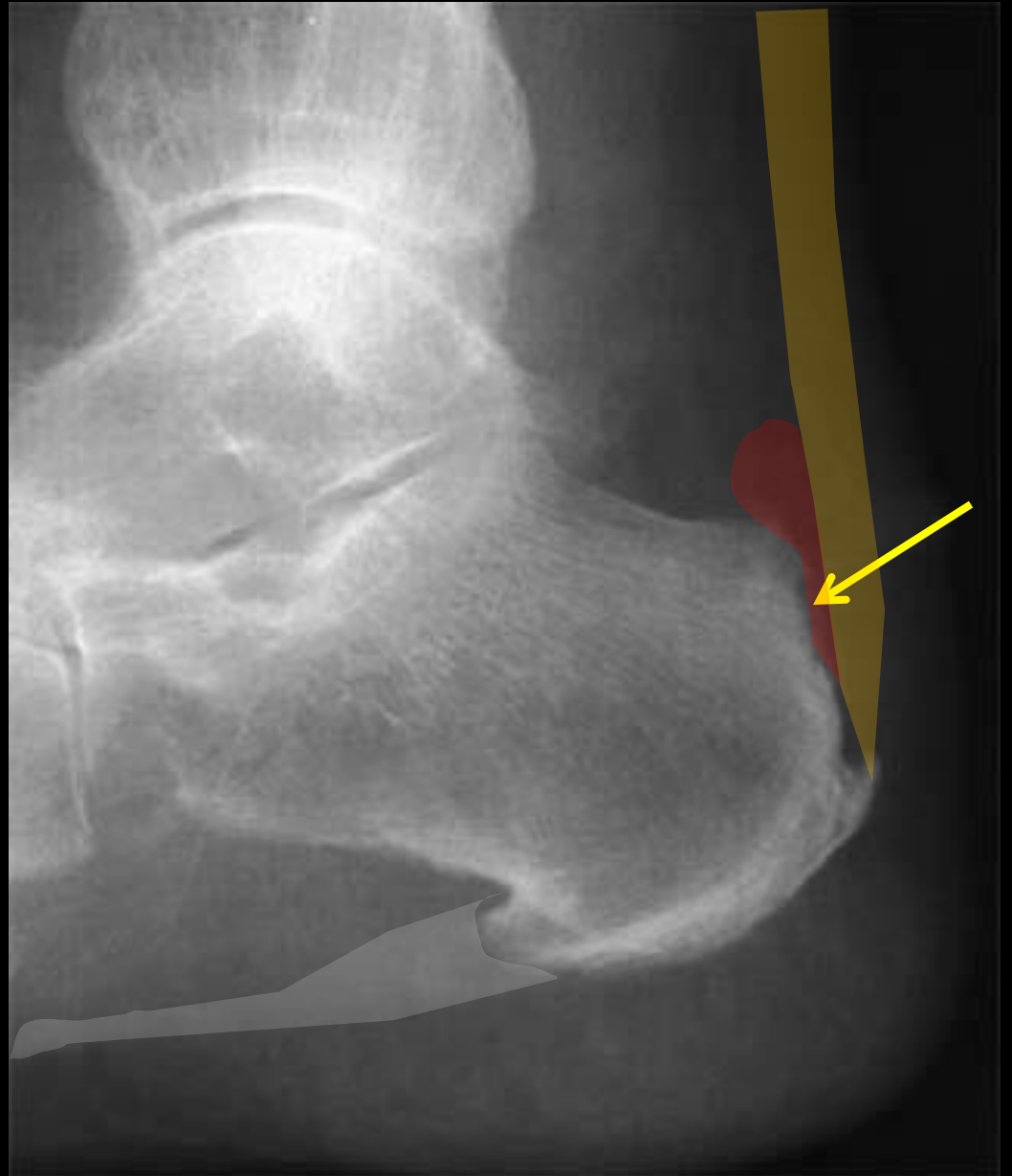
Young men

Urethritis

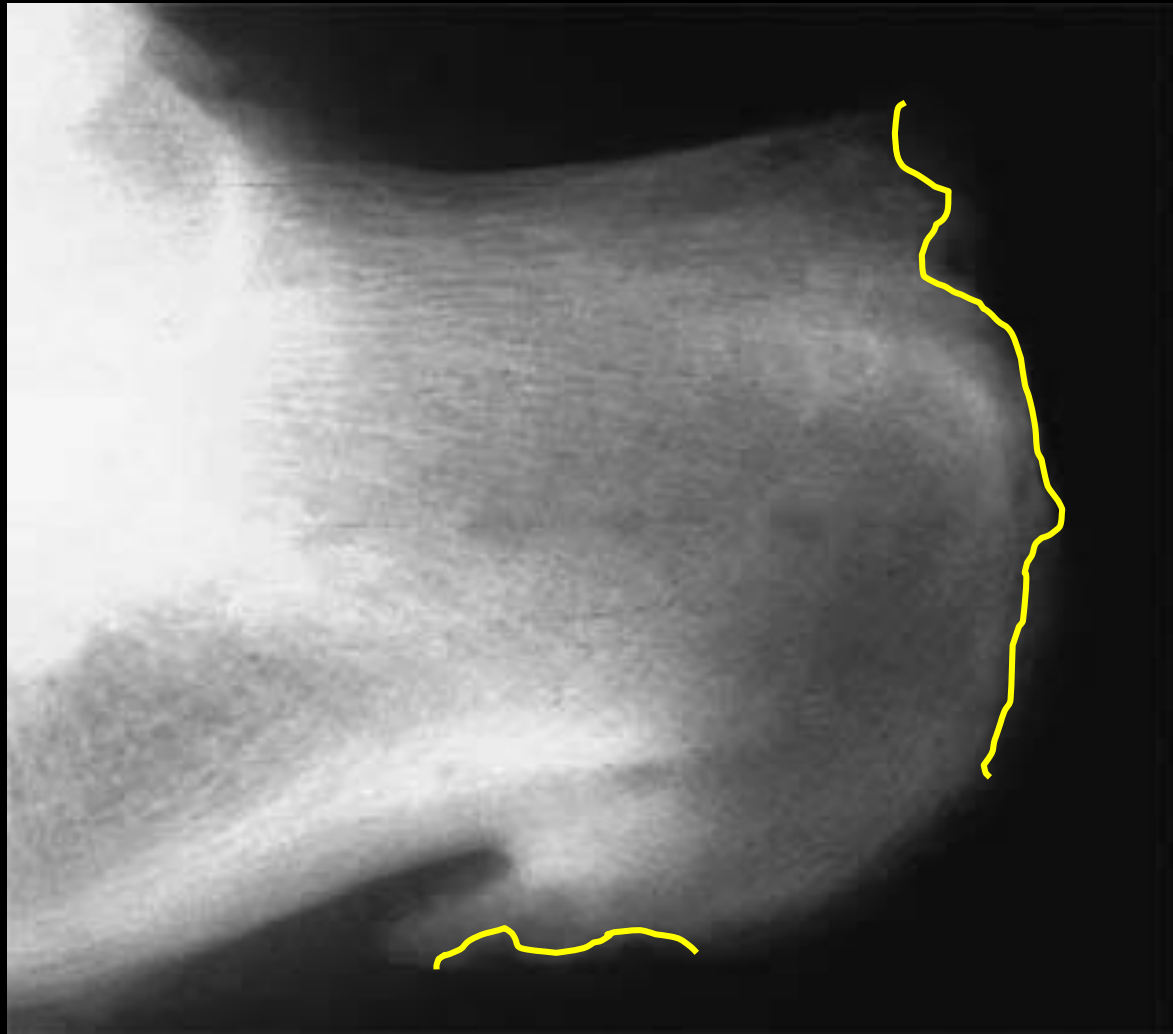Conjunctivitis

Pre-Achilles bursitis

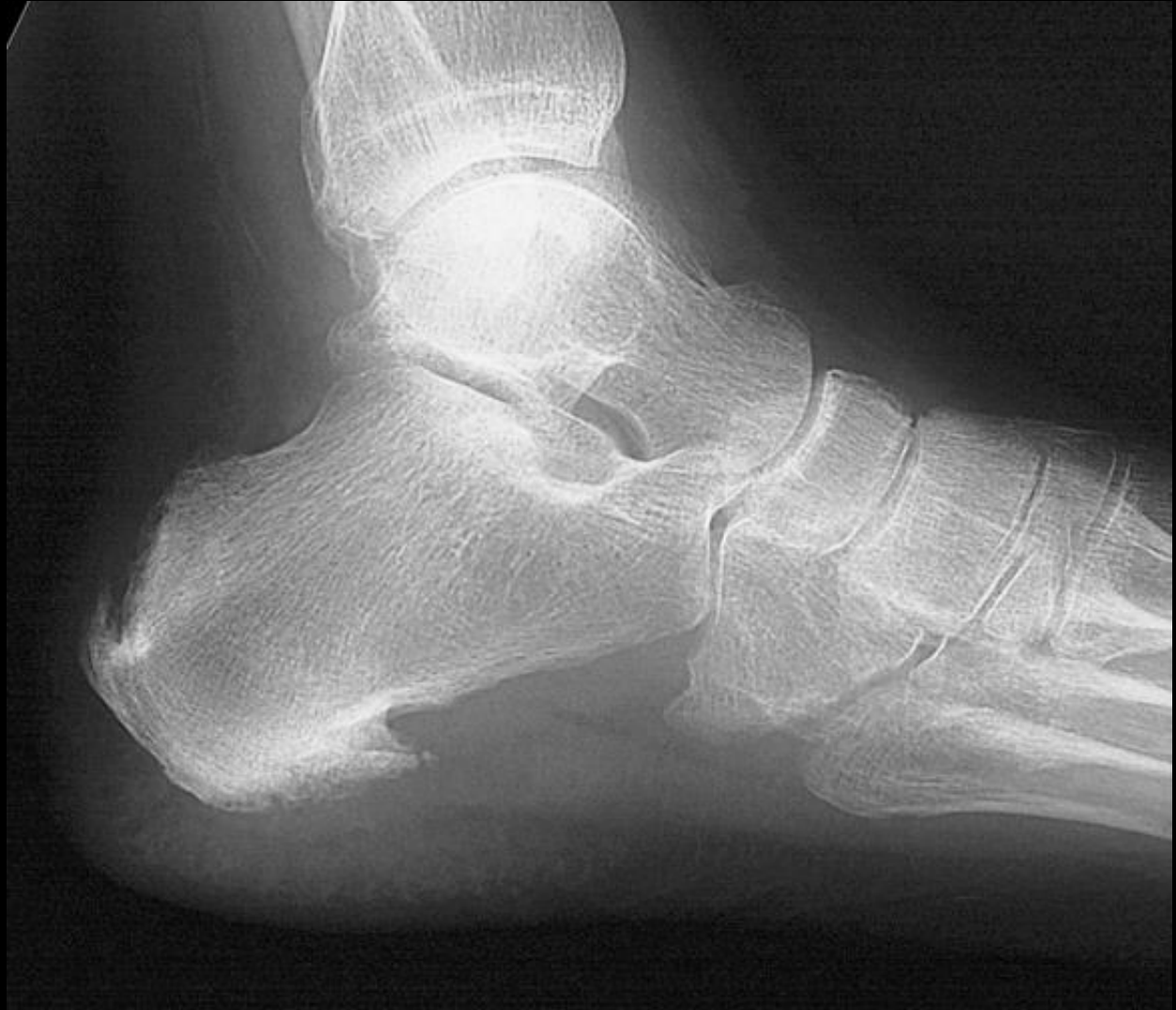Plantar fasciitis

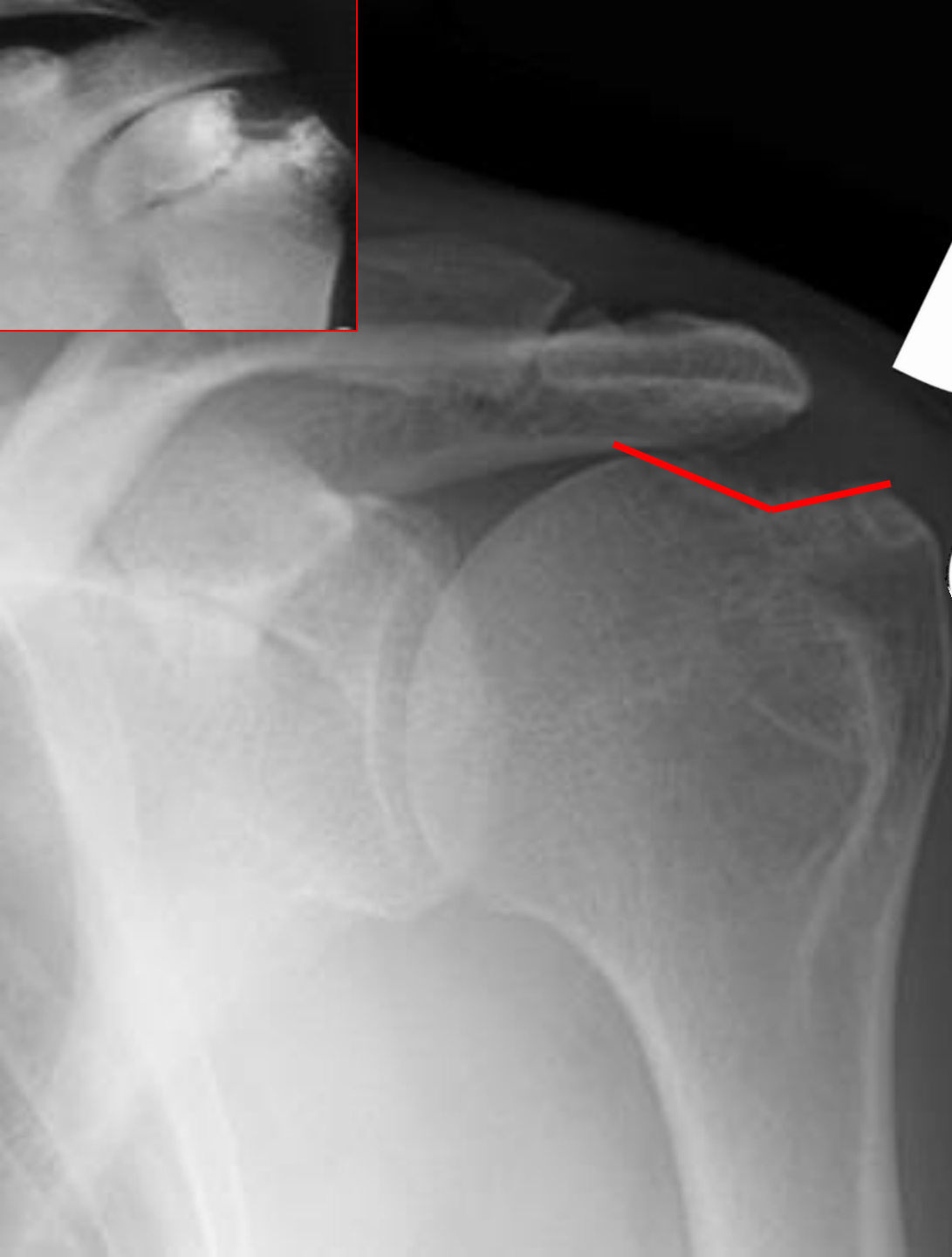


Reiter's disease

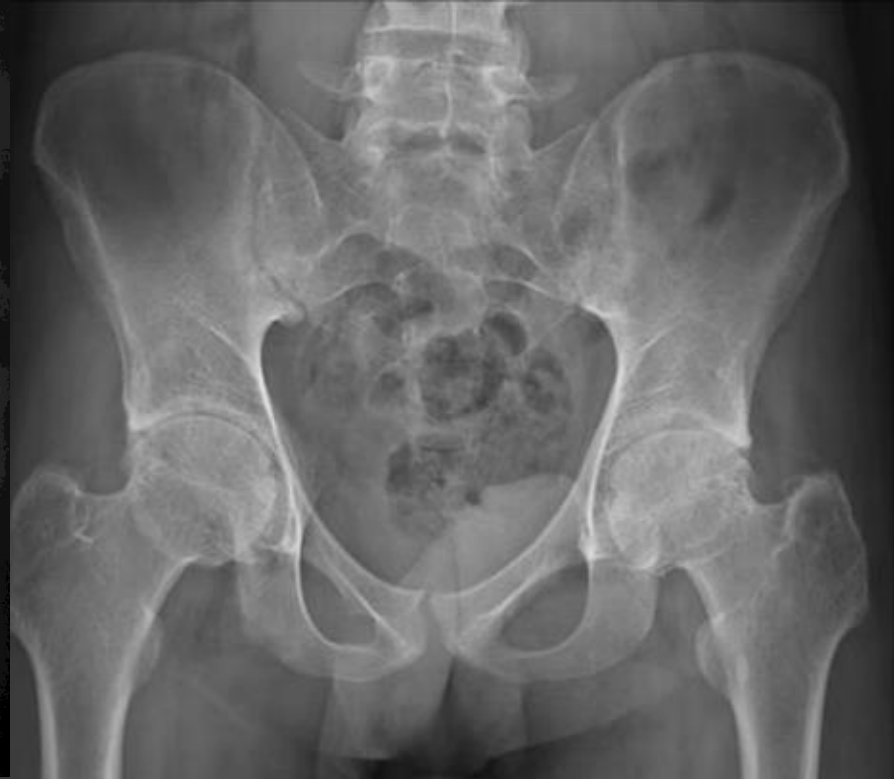
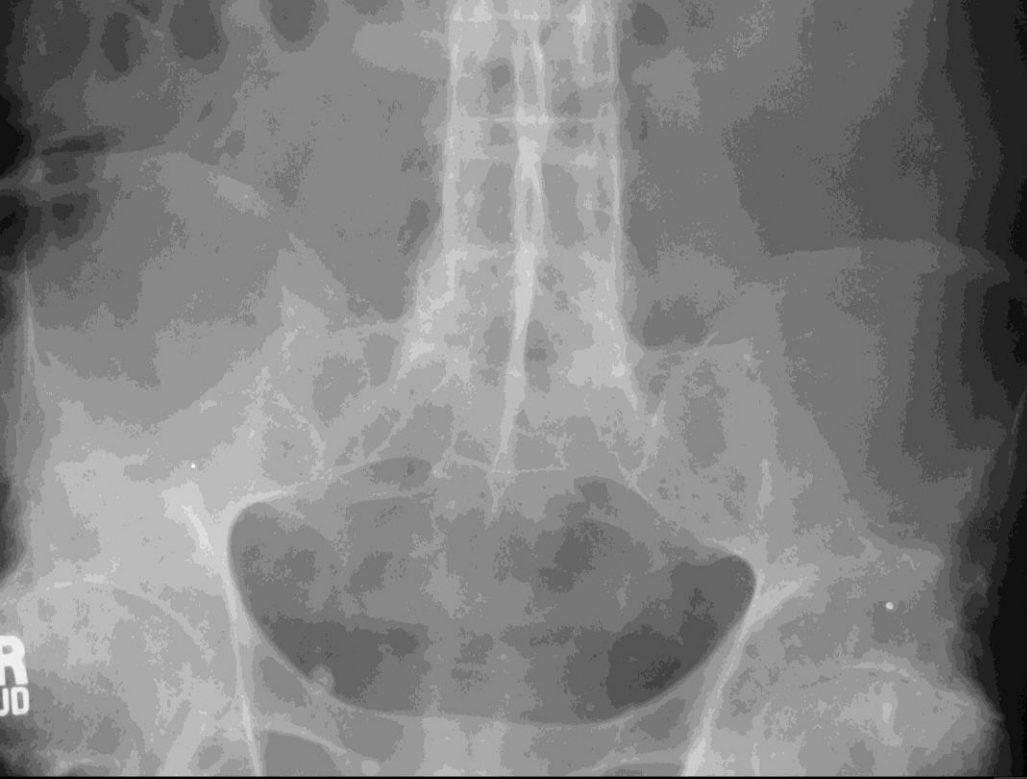
Psoriatic arthritis

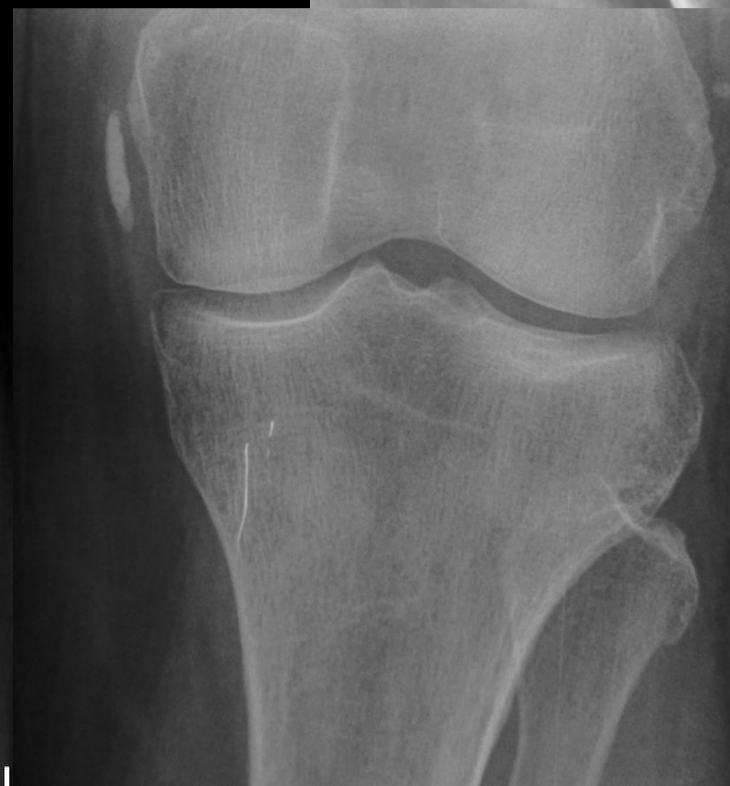
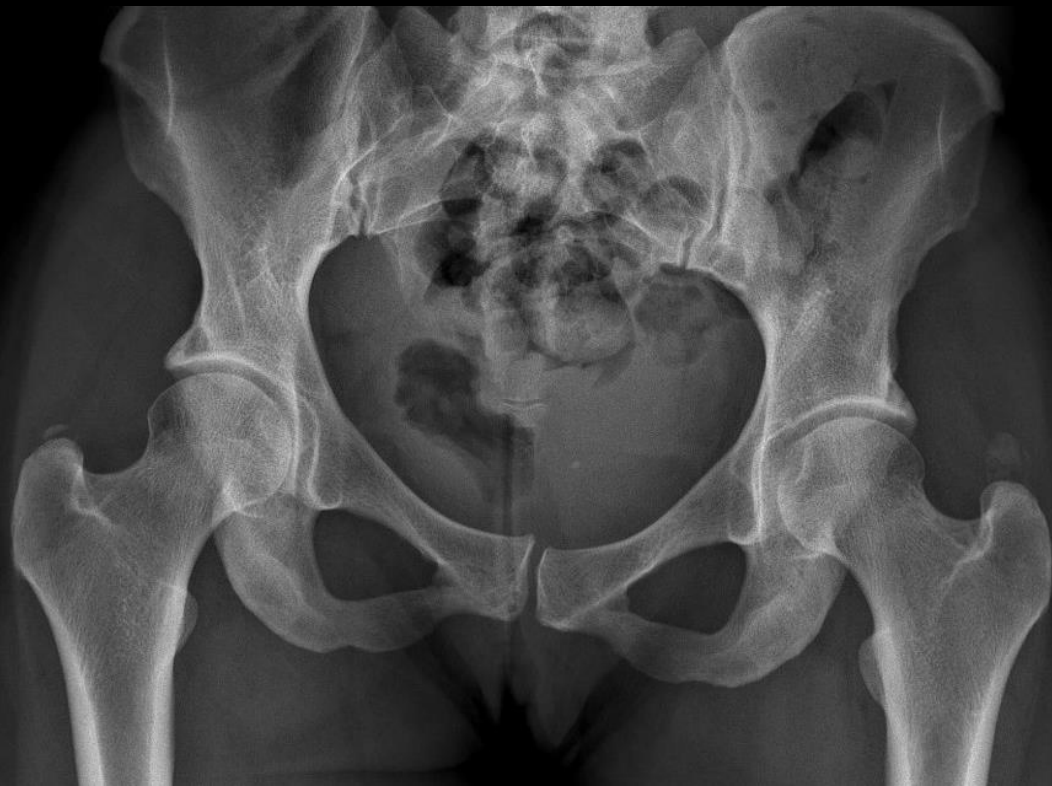
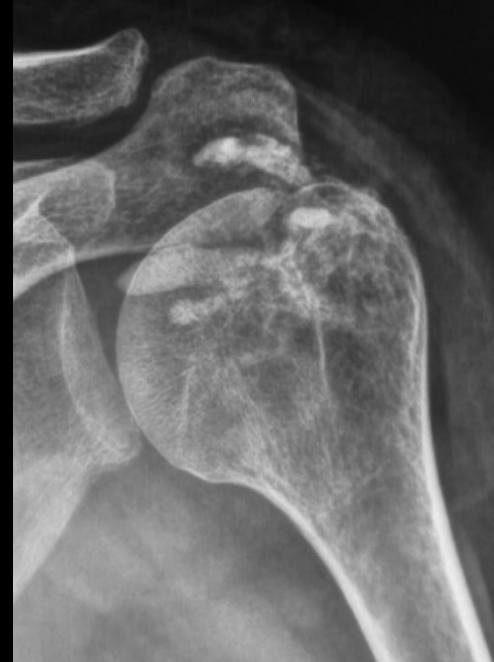

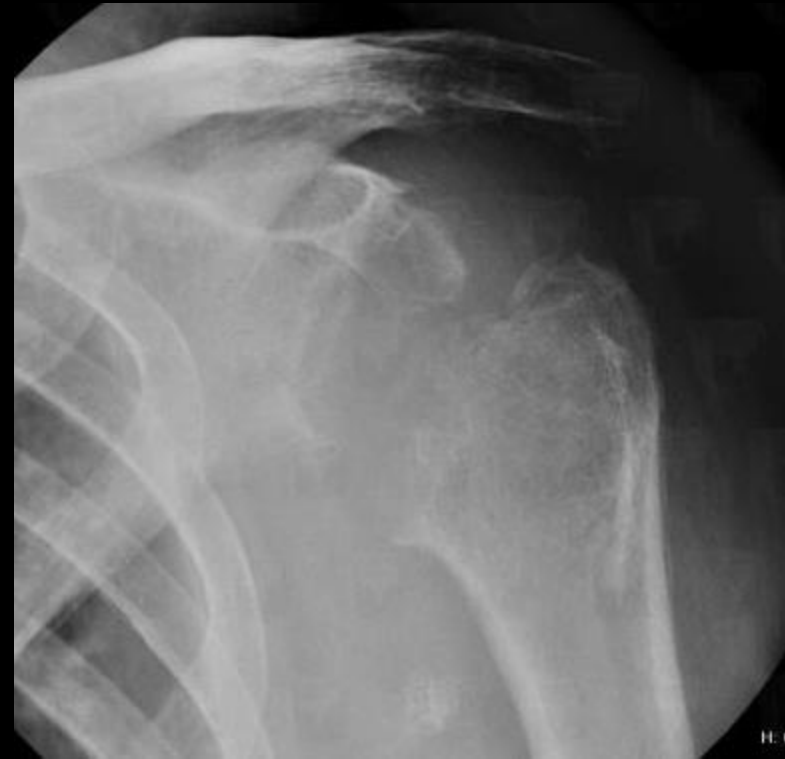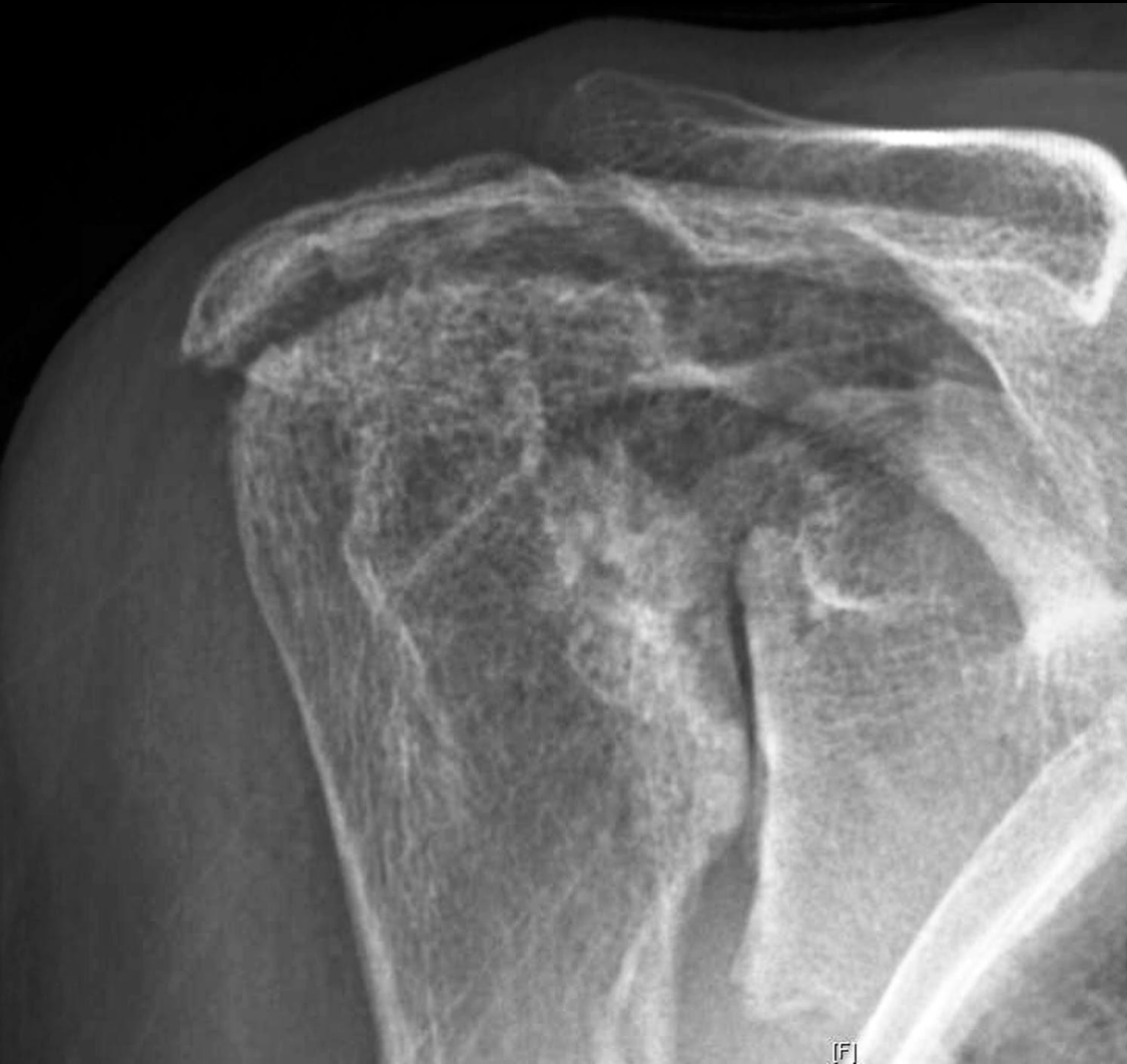
“Hatchet” sign



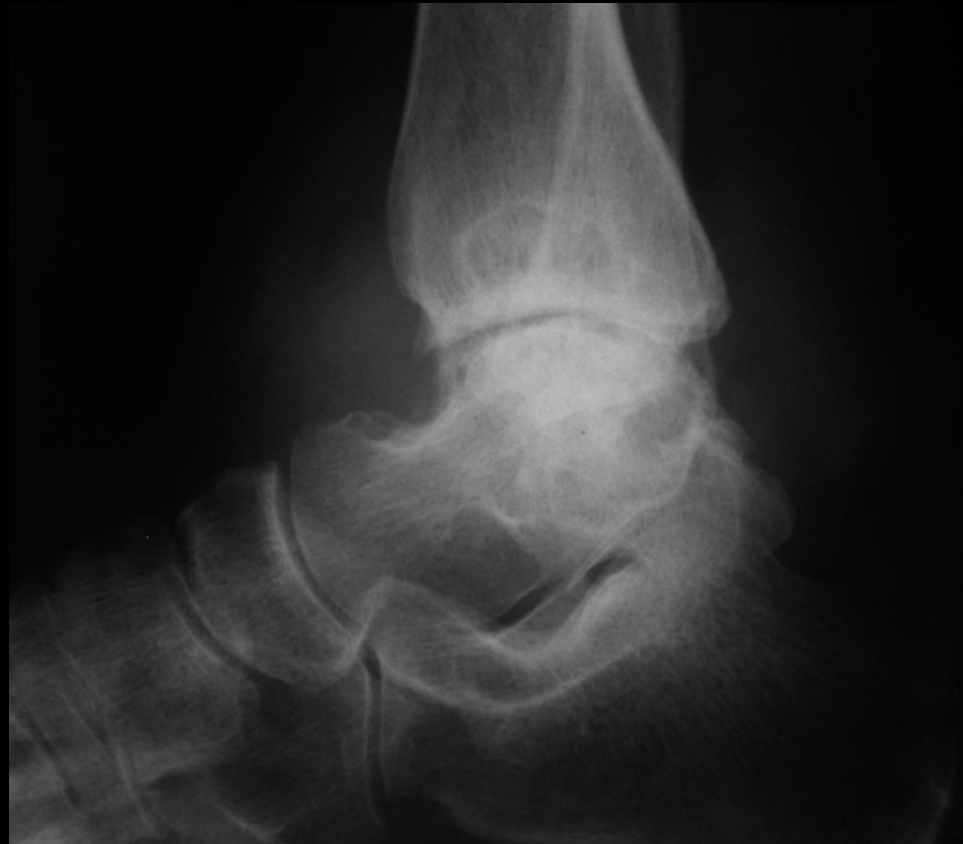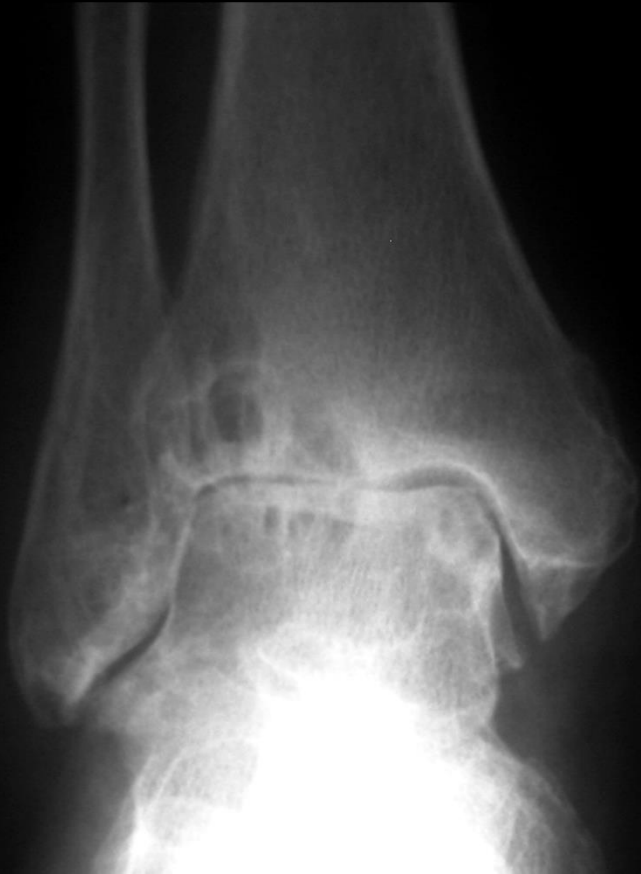HADD - BCP



Milwaukee shoulder syndrome



PVNS, 64f



Ευχαριστώ

