



# Ασθενείς με κακοήθεια που λαμβάνουν ανοσοθεραπεία και tocilizumab

Γεώργιος Δεμιρτζόγλου  
Ειδικευόμενος ρευματολογίας,  
Μονάδα ρευματολογίας και κλινικής ανοσολογίας, ΠΓΝ  
Αττικών


ΔΕΝ ΥΠΑΡΧΕΙ ΣΥΓΚΡΟΥΣΗ ΣΥΜΦΕΡΟΝΤΩΝ

# ΠΕΡΙΕΧΟΜΕΝΑ ΠΑΡΟΥΣΙΑΣΗΣ

- Παρουσίαση κλινικών περιπτώσεων
- Προβληματισμοί –κριτική αξιολόγηση
- Κατευθυντήριες οδηγίες
- Βασική ανοσολογία
- Clinical trials- Real world evidence
- Take Home Messages


# Παρουσίαση κλινικής περίπτωσης 1

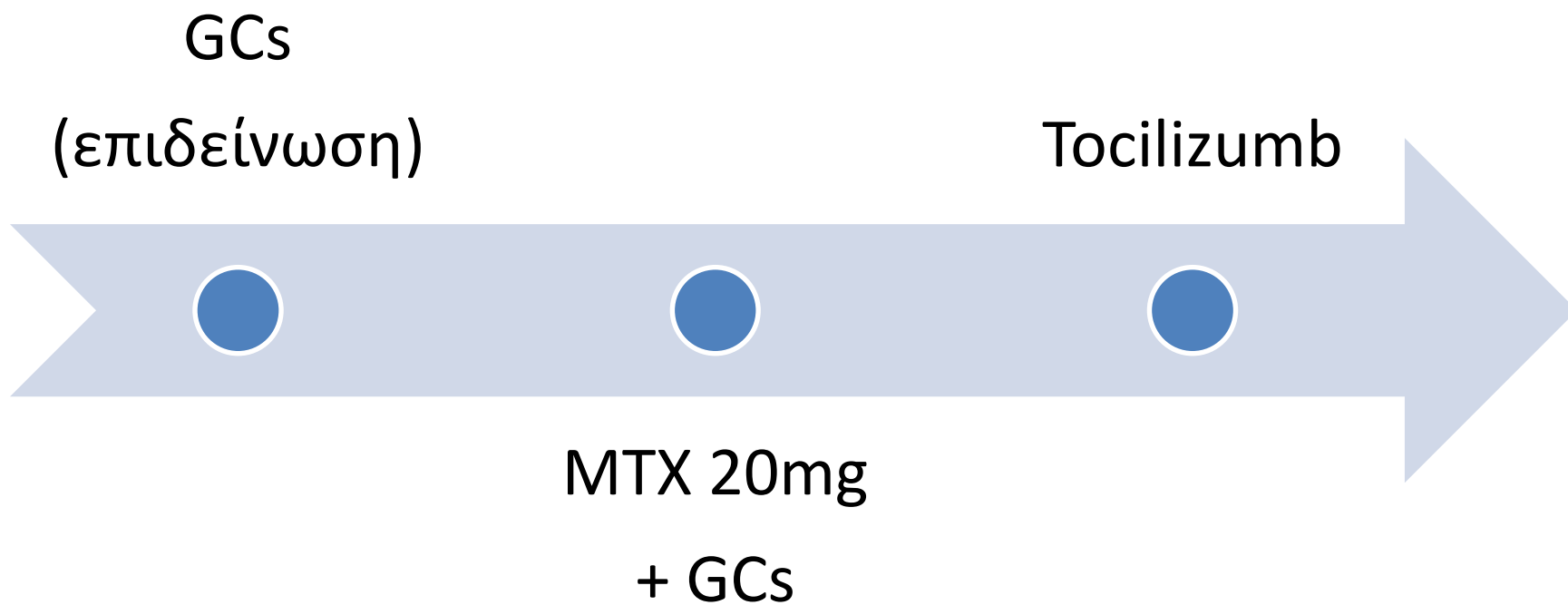
- Γυναίκα, 73
- α/α ΣΔτ2 , ΑΥ,
- Μεταστατικό μελάνωμα υπό nivolumab + ipilimumab
- Συμμετρική πολυαρθρίτιδα τύπου RA → Διακοπή ανοσοθεραπείας
- Διπλά οροθετική
- Καμία ανταπόκριση σε GCs +MTX 20mg
- Προσθήκη tocilizumab → LDA



# Παρουσίαση κλινικής περίπτωσης 2

- Αντρας, 59
- Πλακώδες ca λάρυγγα  
→ ΧΜΘ/ ΑΚΘ και  
nivolumab για  
συντήρηση
- Συμμετρική  
πολυαρθρίτιδα ΜΚΦ,  
Εφφ, ΠΧΚ, γονάτων
- Αρνητικός  
ανοσολογικός έλεγχος





# Προβληματισμοί

- Είναι δόκιμη η χορήγηση bDMARDs ;
- Σε ποιόν ασθενή;
- Ποιο bDMARD;
- Anti TNF vs Anti IL-6 ;
- Κίνδυνοι και οφέλη ;

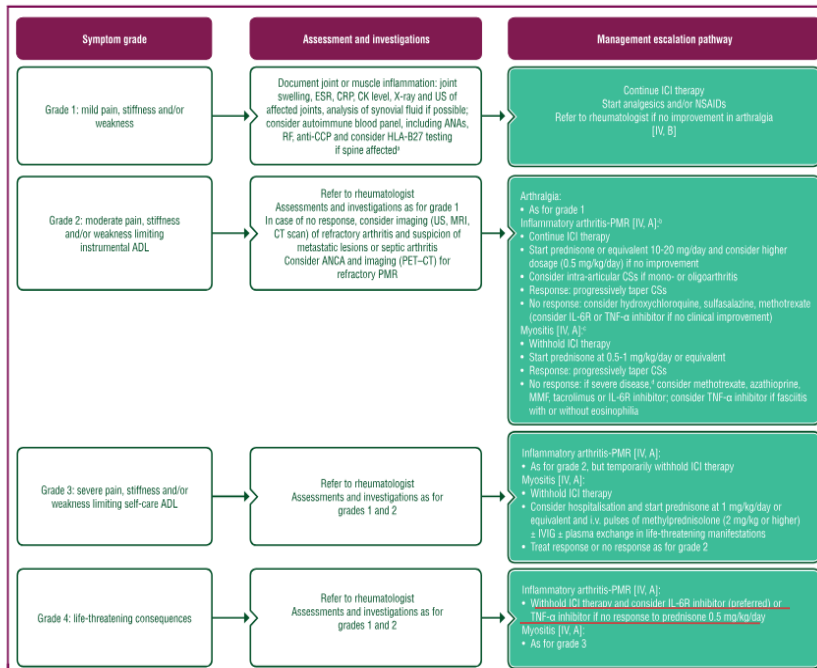
# Κατευθυντήριες οδηγίες

## EULAR- ESMO

## ASCO

Annals of Oncology

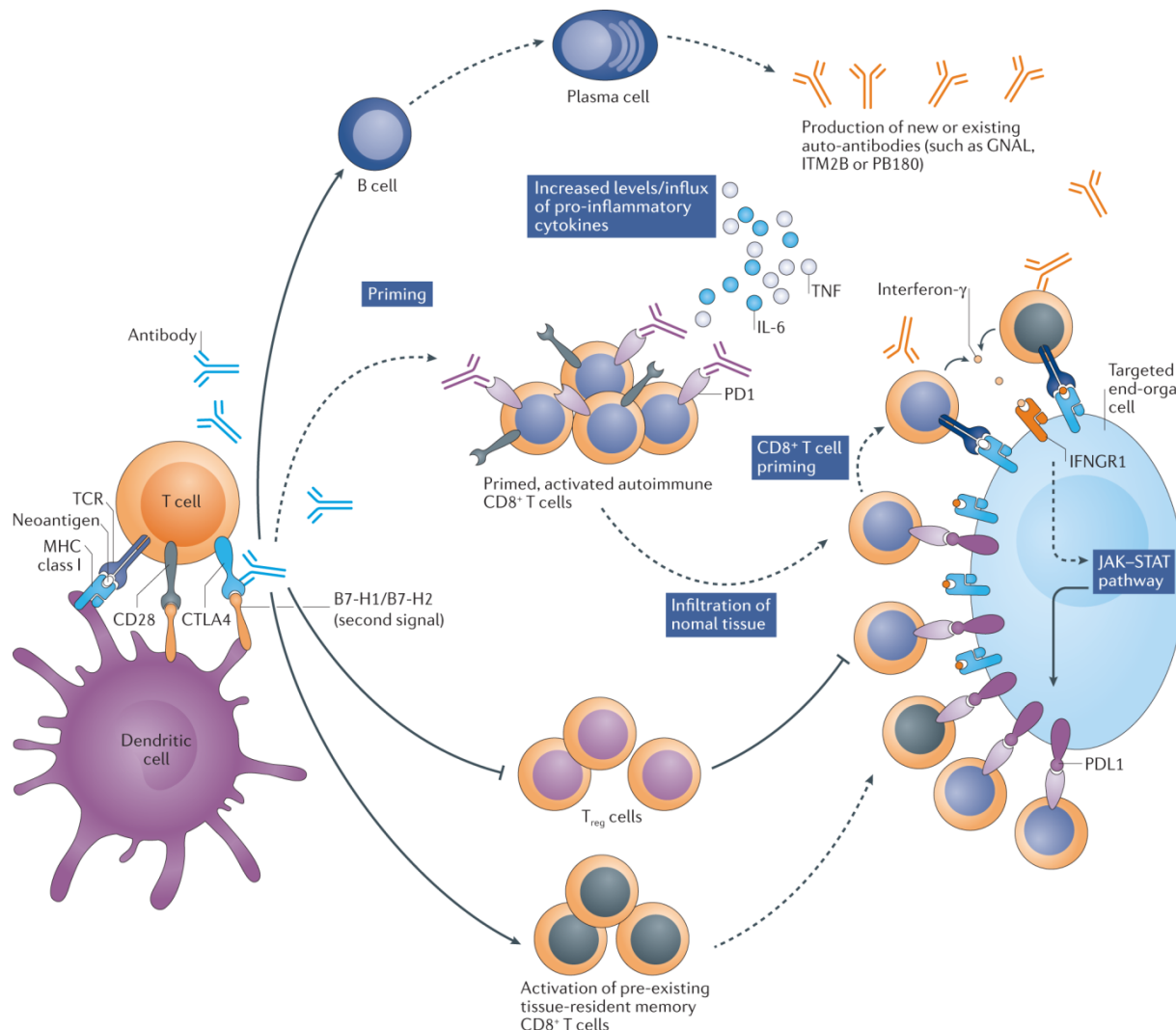
J. Haanen et al.



Grading	Management
All grades	Clinicians should follow reports of new joint pain to determine if IA is present. Question whether symptoms new since receiving ICPI.
G1: Mild pain with inflammation, erythema, or joint swelling	Continue ICPI. Initiate analgesia with acetaminophen and/or NSAIDs.
G2: Moderate pain associated with signs of inflammation, erythema, or joint swelling; limiting instrumental ADL	Consider holding ICPI. Escalate analgesia and consider higher doses of NSAIDs as needed. If inadequately controlled, initiate prednisone 10-20 mg/d or equivalent. If improvement, slow taper according to response during the next 4-6 weeks. If no improvement after initial 4 weeks treat as G3. If unable to lower corticosteroid dose to below 10 mg/d after 6-8 weeks, consider DMARD. Consider intra-articular steroid injections for large joints. Referral to rheumatology.
G3-4: Severe pain associated with signs of inflammation, erythema, or joint swelling; irreversible joint damage; disabling and limiting self-care ADL	Hold ICPI temporarily and may resume in consultation with rheumatology, if recover to $\leq$ G1. Initiate oral prednisone 0.5-1 mg/kg. If failure of improvement after 2 weeks or worsening in meantime, consider synthetic or biologic DMARD. Synthetic: methotrexate, leflunomide, hydroxychloroquine, and sulfasalazine alone or in combination. <u>Biologic: Consider anticytokine therapy such as TNF<math>\alpha</math> or IL-6 antagonists.</u> Note: As a caution, IL-6 inhibition can cause intestinal perforation. <sup>126</sup> Although this is extremely rare, it should not be used in patients with concomitant immune-related colitis. Referral to rheumatology.
Additional considerations	
Early recognition is critical to avoid erosive joint damage. Corticosteroids can be used as part of initial therapy in IA, but because of likely prolonged treatment requirements, physicians should consider starting steroid-sparing agents earlier than one would with other irAEs. Oligoarthritis can be treated early on with intra-articular steroids, consider early referral.	

Δύνεται να χορηγηθεί anti-IL6 (preferred ESMO) ή anti- TNF ακόμα και μαζί με την ανοσοθεραπεία!

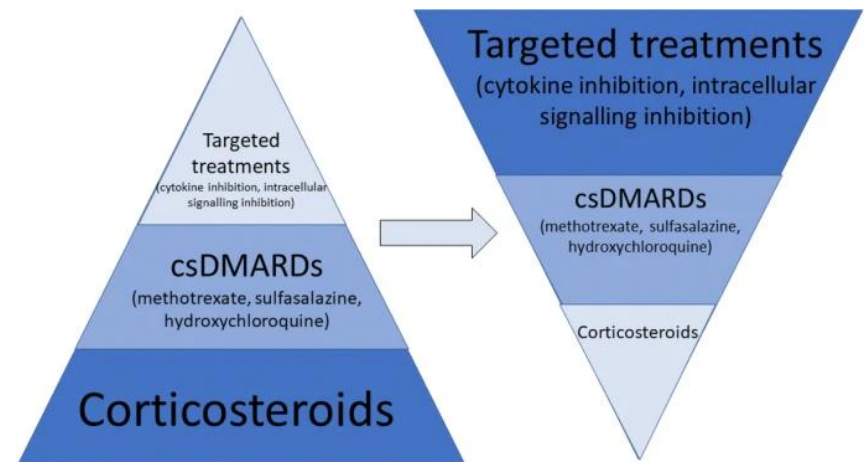
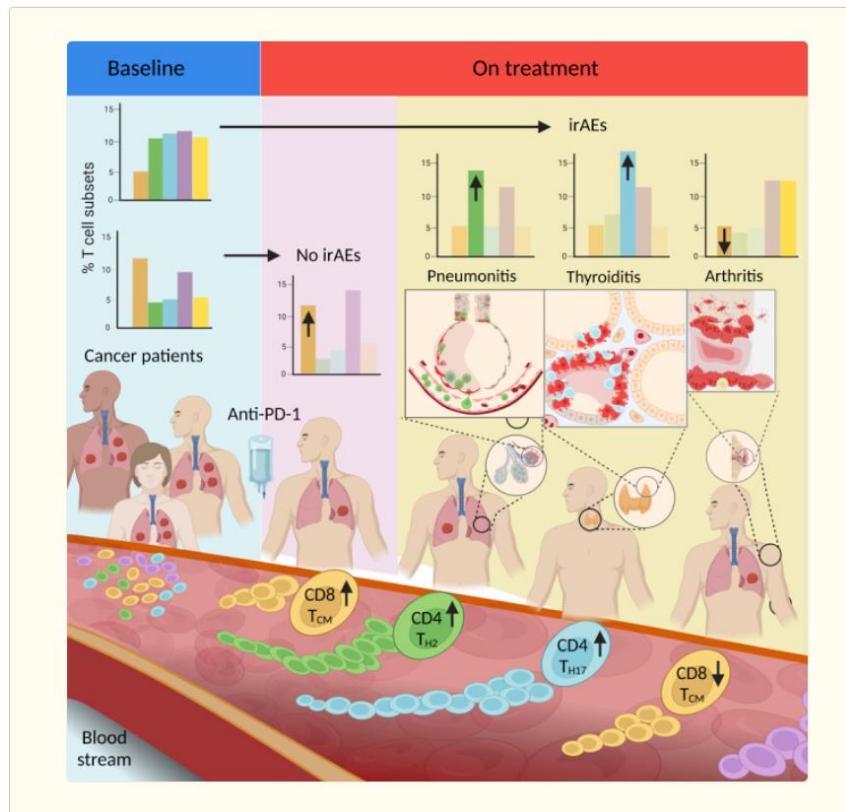




# για

- Αυξημένη ενεργοποίηση CD8+ T λεμφοκυττάρων → ιστική καταστροφή
- Ενεργοποίηση T μνημονικών κυττάρων
- Παραγωγή χαμηλών τίτλων αυτοαντισωμάτων
- Αναστολή Tregs





# Clinical trials- Real world evidence

☐ NCT04940299 Active, not recruiting  
Tocilizumab, Ipilimumab, and Nivolumab for the Treatment of Advanced Melanoma, Non-Sm  
Conditions  
Clinical Stage III Cutaneous  
Locally Advanced Bladder  
Locations  
Houston, Texas, United States

☐ NCT04258150 Active, not recruiting  
Ipilimumab, Nivolumab, and Atezolizumab for the Treatment of Advanced Pancreatic Cancer  
Conditions  
Pancreatic Cancer  
Locations  
Herlev, Denmark

☐ NCT03999749 Active, not recruiting  
A Phase II Study of the Combination of Atezolizumab and Nivolumab in Stage III or Stage IV Melanoma  
Conditions  
Melanoma  
Locations  
Los Angeles, California, United States  
New York, New York, United States

> Eur J Intern Med. 2021 Nov;93:87-94. doi: 10.1016/j.ejim.2021.07.016. Epub 2021 Aug 12.

Immune-related  
adverse events: a literature review and a


[Home](#) > [Cancer Immunology, Immunotherapy](#) > Article

## Dual efficacy of tocilizumab in managing PD-1 inhibitors-induced myocardial inflammatory injury and suppressing tumor growth with PD-1 inhibitors: a preclinical study

Research | [Open access](#) | Published: 03 January 2025


Volume 74, article number 52, (2025) [Cite this article](#)

[Download PDF](#) 

 You have full access to this [open access](#) article

Lazzari<sup>4</sup>,  
Signale<sup>5</sup>,  
Arc<sup>4</sup>,

inhibitor-  
the TAPIR study

[Yanxin Chen](#), [Yuxi Luo](#), [Yunwei Liu](#), [Daya Luo](#) & [Anwen Liu](#) 

# Clinical trials- Real world evidence


☐ **NCT05034536** **Recruiting**

PD-1 Antibody Therapy + Infliximab for Metastatic Melanoma

Conditions

Metastatic Melanoma

Locations

 Boston, Massachusetts, United States


☐ **NCT02763761** **Withdrawn**

An Investigational Study of Infliximab With Prednisone or Methylprednisolone Versus Prednisone Combination Treatment in Immune Related or Severe Diarrhea in Patients Treated With Yervoy and/or Opdivo

Conditions


Lung Cancer   Melanoma   Renal Cell Carcinoma

Locations

 Los Angeles, California, United States

 Aurora, Colorado, United States

 Tampa, Florida, United States

 Atlanta, Georgia, United States

[Show all 10 locations](#)

☐ **NCT03293784** **Completed**

TNF-Inhibitor as Immune Checkpoint Inhibitor for Advanced MELanoma

Conditions

Melanoma

Locations

 Toulouse, France

☐ **NCT04991025** **Recruiting**


Adding Certolizumab to Chemotherapy + Nivolumab in People Who Have Lung Cancer That Can Be Treated With Surgery

Conditions

Lung Cancer   Lung Cancer Stage II   Lung Cancer Stage III

Locations

 Basking Ridge, New Jersey, United States

 Middletown, New Jersey, United States


 Montvale, New Jersey, United States


 Commack, New York, United States

[Show all 7 locations](#)

Clinical/translational cancer immunotherapy

Original research

Management of infliximab refractory immune checkpoint inhibitor gastrointestinal toxicity: a multicenter case series 

 Catriona Harvey <sup>1, 2</sup>, Kazi J Nahar <sup>2, 3</sup>, Janet McKeown <sup>2, 3</sup>,  Serigne N Lo <sup>4, 5</sup>, Sheima Farag <sup>6</sup>, Nadia Yousaf <sup>6</sup>, Kate Young <sup>6</sup>, Liselotte Tas <sup>7</sup>, Aafke Meerveld-Eggink <sup>7</sup>, Christian Blank <sup>7</sup>, Austin Thomas <sup>8</sup>, Jennifer McQuade <sup>9</sup>,  Bastian Schilling <sup>10</sup>, Douglas B Johnson <sup>11</sup>, Roberto Martín Huertas <sup>12</sup>, Ana Arance <sup>13</sup>, Joanna Lee <sup>3, 14</sup>,  Lisa Zimmer <sup>15</sup>, Georgina V Long <sup>16</sup>, Matteo S Carlino <sup>1</sup>,  Yinghong Wang <sup>17</sup> and Alexander Maxwell Menzies <sup>2, 3</sup>

Correspondence to Dr Alexander Maxwell Menzies; [alexander.menzies@sydney.edu.au](mailto:alexander.menzies@sydney.edu.au)

Su

# Take home messages

- Ανεπιθύμητες ενέργειες από το μυοσκελετικό → ποιότητα ζωής και θεραπευτικό πλάνο
- Μη ανταπόκριση σε GCs + DMARDs → χρήση bDMARD
- Tocilizumab ή AntiTNF (INF)
- Σκέψη και για συγχορήγηση ανοσοθεραπείας με bDMARDs

# Σας ευχαριστώ

